

# Histopathological and Immunohistochemical Diagnosis of Spleen Lymphoma with Atypical Clinical Presentation: Case Report

doi: <https://doi.org/10.32635/2176-9745.RBC.2021v67n4.1432>

*Diagnóstico Histopatológico e Imuno-histoquímico de Linfoma de Baço com Apresentação Clínica Atípica: Relato de Caso*  
Diagnóstico Histopatológico e Imuno-histoquímico de Linfoma de Bazo con Presentación Clínica Atípica: Relato de Caso

Gabrielle Ruthes Fragoso<sup>1</sup>; Eduardo Pires dos Santos<sup>2</sup>; Camila Moraes Marques<sup>3</sup>; Renata Bernardini de Lima<sup>4</sup>

## ABSTRACT

**Introduction:** Both the splenic angiosarcoma and the B-cell non-Hodgkin's lymphoma (NHL) are not only rare but are challenging to diagnose. **Case report:** Male patient, 45 years old, obese, night sweats for one year, and cyclic abdominal pain for two years, with an initial clinical diagnosis of angiosarcoma, however after immunohistochemistry test, it was revealed a B-cell NHL with atypical presentation. The total abdomen ultrasound (US) performed at the onset of the night sweating symptom showed no alterations. After one year, the US showed a splenic mass. Magnetic resonance imaging of the abdominal region revealed a heterogeneous expansive splenic lesion in the anterior aspect with suspected splenic angiosarcoma. After full splenectomy, caudal pancreatectomy, and retroperitoneal lymphadenectomy, histological analysis showed an area of poorly differentiated necrotic malignancy infiltrated in the splenic parenchyma. Immunohistochemical analysis was positive for CD20 reagents in several foci, BCL2, and for KI67 (in ninety percent of the neoplastic cell nucleus). Histopathology and immunohistochemistry are consistent with high-grade, diffuse, NHL of immunophenotype B in the spleen, with no sign of metastasis to adjacent tissues. After total splenectomy and four rounds of chemotherapy, the patient had remission of the tumor and was asymptomatic. **Conclusion:** It is extremely important to recognize the relevance of the correct diagnosis of rare neoplasms such as the one reported. Both clinical and imaging tests, although important, can be inaccurate, reiterating the importance of complementary histologic and immunohistochemical tests.

**Key words:** Splenic Neoplasms/diagnosis; Lymphoma, Non-Hodgkin/diagnosis; Case Reports.

## RESUMO

**Introdução:** Tanto o angiossarcoma esplênico quanto o linfoma não Hodgkin (LNH) de células B não são raros como apresentam desafios diagnósticos. **Relato do caso:** Paciente do sexo masculino, 45 anos, obeso, sudorese noturna há um ano, e dor abdominal cíclica há dois, com clínica inicial de angiossarcoma, contudo, sob o exame histopatológico e imuno-histoquímico, mostrou tratar-se de LNH de células B com apresentação atípica. A ultrassonografia (US) de abdome total realizada ao início do sintoma de sudorese noturna não teve alterações. Após um ano, a US apresentou massa esplênica. Na ressonância magnética da região abdominal, constatou-se tumoração esplênica expansiva heterogênea no aspecto anterior, suspeita de angiossarcoma esplênico. Após esplenectomia total, pancreatectomia caudal e linfadenectomia retroperitoneal, o exame histopatológico mostrou neoplasia maligna pouco diferenciada extensamente necrótica substituindo o parênquima esplênico. O estudo imuno-histoquímico foi positivo para os marcadores CD20 em diversos focos, para o BCL2 e para o KI67 (em 95% dos núcleos das células neoplásicas). A histopatologia e a imuno-histoquímica foram compatíveis com o diagnóstico de LNH difuso de alto grau, com imunofenótipo B do baço, sem sinal de infiltração de tecidos adjacentes. Após a esplenectomia total e quatro ciclos de quimioterapia, o paciente estava livre do linfoma e sem sintomas. **Conclusão:** É de suma importância o reconhecimento do diagnóstico correto de neoplasias raras como a relatada. Tanto a clínica quanto os exames de imagem, mesmo que fundamentais, podem ser imprecisos, reiterando a importância dos exames histológico e imuno-histoquímico complementares. **Palavras-chave:** Neoplasias Esplênicas/diagnóstico; Linfoma não Hodgkin/diagnóstico; Relatos de Casos.

## RESUMEN

**Introducción:** El angiossarcoma esplénico e el linfoma no Hodgkin (LNH) de células B no solo son raros sino que presentan un reto diagnóstico. **Relato del caso:** Paciente masculino de 45 años, obeso, con sudoración nocturna durante un año y dolor abdominal cíclico durante dos años, con clínica inicial de angiossarcoma, pero bajo inmunohistoquímica mostró LNH de células B con presentación atípica. En la ecografía de abdomen total realizada al comienzo del síntoma de sudoración nocturna no hubo cambios. Después de un año, la ecografía enseñó una masa esplénica. La resonancia magnética de la región abdominal reveló una lesión esplénica expansiva heterogénea en la cara anterior, sospechosa de angiossarcoma esplénico. Tras la esplenectomía total, la pancreatectomía caudal y la linfadenectomía retroperitoneal, el análisis histológico mostró un área de neoplasia maligna necrótica poco diferenciada infiltrada en el parénquima esplénico. El análisis inmunohistoquímico fue positivo para los reactivos CD20 en varios focos, BCL2 y KI67 en el 95% del núcleo celular, la histología y la inmunohistoquímica son consistentes con LNH difuso de alto grado de inmunofenotipo B en el bazo, sin signos de metástasis. Tras esplenectomía total y cuatro rondas de quimioterapia, el paciente presentó remisión del tumor, así como disminución de síntomas. **Conclusión:** Es de suma importancia reconocer el diagnóstico de neoplasias raras como la reportada. Tanto las pruebas clínicas como las de imagen, aunque fundamentales, pueden ser inexactas, reiterando la importancia de las pruebas histopatológicas e inmunohistológicas. **Palabras clave:** Neoplasias del Bazo/diagnóstico; Linfoma no Hodgkin/diagnóstico; Informes de Casos.

<sup>1-3</sup>Faculdades Pequeno Príncipe (FPP). Curitiba (PR), Brazil. E-mails: gabiruthesfragoso@gmail.com; eduardo23.ps@outlook.com; camilam14@gmail.com. Orcid iD: <https://orcid.org/0000-0002-7965-9988>; Orcid iD: <https://orcid.org/0000-0003-2336-1338>; Orcid iD: <https://orcid.org/0000-0001-5121-922X>

<sup>4</sup>Hospital Erasto Gartner (HEG). Curitiba (PR), Brazil. E-mail: renabl@gmail.com. Orcid iD: <https://orcid.org/0000-0001-7484-9259>

**Corresponding author:** Gabrielle Ruthes Fragoso. Avenida Iguaçú, 333 – Reboças. Curitiba (PR), Brazil. CEP 80230-020. E-mail: gabiruthesfragoso@gmail.com



## INTRODUCTION

Splenic primary tumors are extremely rare. Angiosarcoma represents less than 1% of soft tissues sarcoma and only a small part of the cases onsets in the spleen. Frequently, they are challenging for the pathologist to diagnose because of the histopathology variations. The development of new markers in immunohistochemistry panels as CD31 is instrumental to discard other differential diagnosis. Primary splenic angiosarcoma is associated with very poor prognosis due to difficulty to diagnose and its high metastatic potential<sup>1,2</sup>. On the other hand, Hodgkin lymphomas (HL) affect lymph nodes, spleen and bone marrow mainly and non-Hodgkin lymphomas (NHL) can present extranodal manifestations in nearly 25% of the cases, more frequently in the stomach, skin, oral cavity, small intestine and central nervous system<sup>3</sup>. The main signs and symptoms of lymphomas in general are the presence of tumoral masses, further to fatigue and cutaneous pruritus; for phenotype B NHL, typical symptoms are fever, slimming of more than 10% of the weight in six months and night sweats.

The diagnosis of NHL is based in the biopsy of the lymph node or extranodal tumoral mass, a skilled pathologist should test the material to classify the disease according to morphologic and immunohistochemistry criteria<sup>3</sup>.

The goal of this article is to report a case of a patient with initial clinical diagnosis of angiosarcoma, however, the complementary histopathological and immunohistochemistry diagnosis revealed an atypical immunophenotype B NHL presentation.

The Institutional Review Board of “*Faculdades Pequeno Príncipe*”, approved the study, report number 4.163.551.

## CASE REPORT

45 years old male patient, obese (BMI 30.45), with systemic arterial hypertension, hypothyroidism (in treatment) and pre-diabetic. History of hepatitis C with completed treatment three months prior to the onset of the symptoms. No previous surgeries. Ex-smoker, moderate alcohol user. Second degree relatives with history of abdominal cancer. Working with chemicals in the past six months, wears personal protective equipment (PPE).

Reports night sweats for one-year, cyclic abdominal pain in left hypochondrial with two-years evolution. Pain more intense in the last crisis. No fever or weight loss. At physical exam, palpable spleen to deep inspiration without other noticeable findings.

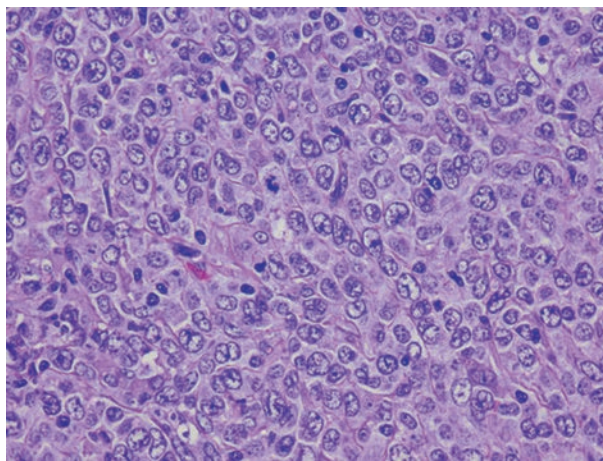
Normal ultrasound of total abdomen performed in the beginning of night sweats. After one year, repeated the

exam, splenic mass was detected. Abdominal magnetic resonance imaging showed expansive splenic tumor, heterogeneous in anterior portion, measuring 136 x 123 x 88 mm. Lymph nodes with augmented dimensions in portocaval region and hepatic hilus measuring until 27 mm, in addition to prominent lymph nodes in portocaval and periaortic retro-peritoneum region measuring until 12 mm. Although it was not possible to determine the nature of the spleen tumor, there was suspicion of splenic angiosarcoma.

Patient submitted to total splenectomy, caudal pancreatectomy and retro-perineum lymphadenectomy to remove and classify the tumor. Left 20 cm subcostal incision found bulky tumor compromising the spleen and absence of peritoneum or hepatic spread. Suspected infiltration in abdominal wall unconfirmed in histopathological exam.

Splenectomy product weighed 1,292 grams, 17 x 15 x 10 cm. Winey-red external lobulated surface partially coated with adipose tissue. At cut, whitish lobulated tumor was detected measuring 15 x 14 x 10 cm, completely replacing the organ.

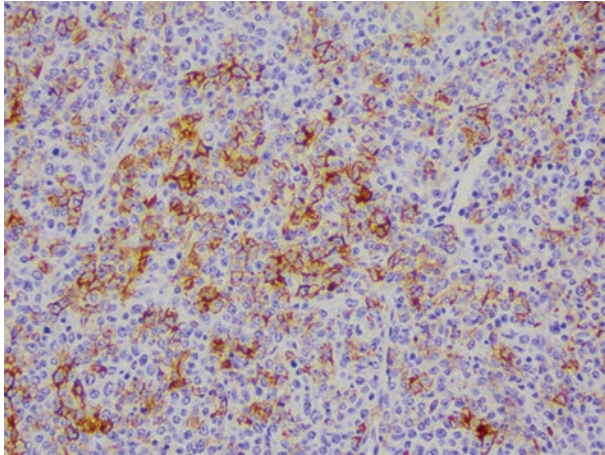
The histopathological exam showed little differentiated extensively necrotic malignant neoplasm substituting the splenic parenchyma (figure 1). The surgical margins were neoplasm-free as well as the 12 lymph nodes of the splenic hilum with preserved histopathological aspect.



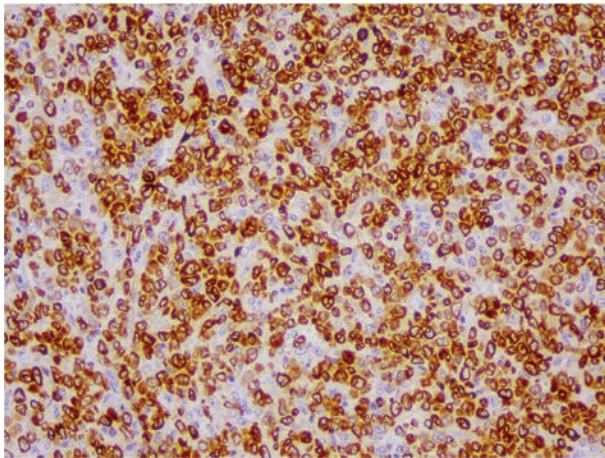
**Figure 1.** In largely enhanced hematoxylin and eosin staining the nuclear morphology of the tumor is seen with large nuclei, clear chromatin (sign of high metabolism) and evident nucleole. A mitotic figure appears in the figure. 400x enhanced image is portrayed

The immunohistochemistry study revealed positivity for markers CD20 (figure 2) in several foci for BCL2 (figure 3) and for KI67 (figure 4) in nearly 95% of the neoplastic cells nuclei. CD3 and CD30 were negative.

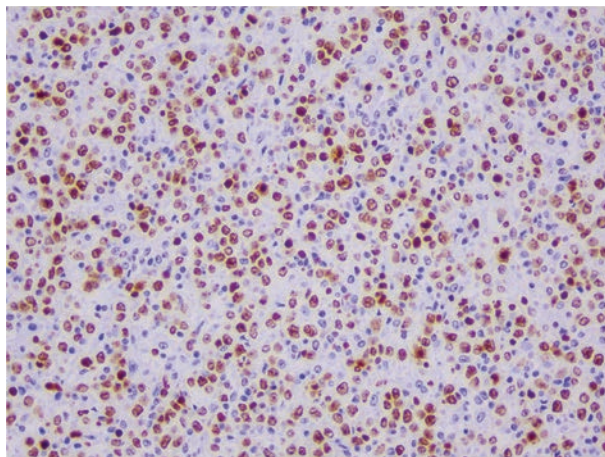
Histopathology and immunohistochemistry were consistent with high grade NHL diffuse immunophenotype B, completely replacing the organ with no signs of neoplastic disease in adjacent regions.



**Figure 2.** Positive malignant neoplasm for multifocal CD20. 200x enhanced image



**Figure 3.** Diffuse reactivity for BCL2. 200x enhanced image



**Figure 4.** High proliferation rates of the neoplasm because of high percentage of positive malignant nuclei cells of Ki67. 200x enhanced image

After total splenectomy followed by four cycles of R-CHOP chemotherapy (rifampicin, cyclophosphamide, hydroxidoxorubicin, vincristine and prednisone), the patient was tumor-free without further symptoms.

## DISCUSSION

Patient had chronic pain in left hypochondrial associated with night sweats complaining for more than two years until a diagnosis was reached.

The first topic standing out is the non-specificity of lab and imaging tests because they hampered the diagnosis, leading to the necessity of more specific diagnostic methods<sup>4</sup>. In this case, despite late diagnosis, complete remission occurred after surgical resection and chemotherapy.

The second point to discuss is the patient symptomatology not consistent with the final diagnosis of high degree phenotype B NHL, since the first diagnostic hypothesis was splenic angiosarcoma. Patient did not report fever, weight loss and increase of lymph nodes. The main complaint, in this case, was persistent abdominal pain associated with night sweats.

Primary splenic tumors are rare and angiosarcomas are even less prevalent of around 1% of soft tissues sarcomas and even lower for primary spleen tumors<sup>1,2</sup>.

For most of HL, the main and initial scenario is the compromise of one or more lymph nodes chain and in more advanced cases, spleen and bone marrow. In cases of NHL, overall, further to the compromise of lymph nodes, systemic manifestations and presence of extranodal foci may occur in nearly 25% of the cases. However, in both diseases, it is rare that the primary tumor is located in the spleen alone. In addition, these represent a type of tumor with extremely rare presentation restricted to only one organ because of its high spread potential<sup>3-5</sup>.

The first diagnostic hypothesis after the clinical interview and imaging tests was angiosarcoma. The initial objective of the splenic surgery was the biopsy for histopathological exam and, if necessary, immunohistochemistry. However, because of the risks and difficulty of surgical access, total splenectomy was the choice. After splenectomy and histopathological and immunohistochemistry studies, the final diagnosis was reached. The histological analysis revealed tumor morphology with presence of large nuclei, high metabolic activity because of clear chromatin and more evident nucleoli and mitosis too (figure 1).

After the histopathological diagnosis of spleen primary lymphoma, the immunohistochemistry of the material was run for its classification<sup>6,7</sup> with positivity for markers CD20 in several foci, for BCL2 and for KI67 in nearly 95% of the nuclei of neoplastic cells with negativity for CD3 and CD30. The definitive diagnostic was consistent with high grade primary diffuse phenotype B NHL of the spleen. There were no signs of neoplastic compromise of the adjacent tissues of the organ removed, the neoplasm was restricted to the spleen<sup>8</sup>, contradicting the highly

infiltrative nature of immunophenotype B NHL<sup>9</sup>. In addition to corroborating the definition of accurate diagnosis, the surgical procedure allowed the complete removal of the tumor.

Next, the patient underwent four cycles of chemotherapy in R-CHOP pharmacologic regimen. Since 2002, this therapeutic regimen is being utilized in the treatment of phenotype B NHL, with nearly 20% improvement of the prognosis<sup>10</sup>. Today, the patient is in complete remission and is being followed up in a reference hospital.

## CONCLUSION

The correct diagnosis of rare malignant neoplasms as reported is highly relevant. Both the clinic and complementary exams and imaging although essential may not help the diagnostic definition. It is always recommended this type of approach, a biopsy and/or surgery to remove completely the compromised surgical piece and the anatomopathological exam. Whenever necessary, a thorough pathological exam should be followed by an additional immunohistochemical study. Mainly in hospitals without oncology service it is paramount for early and correct diagnosis to minimize morbimortality of the oncologic patients avoiding delays of specific treatment because of late diagnosis.

## CONTRIBUTIONS

Gabrielle Ruthes Frago, Eduardo Pires dos Santos and Camila Aparecida Morais Marques contributed substantially for the study conception and/or design, collection, analysis and/or interpretation of the data, wording and critical review. Renata Bernardini de Lima contributed substantially for the study conception/design, collection, analysis and/or interpretation of the data. All the authors approved the final version to be published.

## DECLARATION OF CONFLICT OF INTERESTS

There is no conflict of interests to declare.

## FUNDING SOURCES

None.

## REFERENCES

1. Coppola S, Leva A, Pagni F, et al. Demanding diagnosis of splenic angiosarcoma as cause of delayed treatment of spontaneous splenic rupture: a case report and literature review. *Case Rep Surg.* 2017;2017: 6256102. doi: <https://doi.org/10.1155/2017/6256102>
2. Zhao Q, Dong A, Wang Y, et al. FDG PET/CT in primary splenic angiosarcoma with diffuse involvement of the spleen. *Clin Nucl Med.* 2017;42(10):815-7. doi: <https://doi.org/10.1097/rlu.0000000000001805>
3. Milito CB, Morais JC, Nucci M, et al. Classificação dos linfomas não-Hodgkin: estudo morfológico e imunoistoquímico de 145 casos. *J Bras Patol Med Lab.* 2002;38(4):315-24. doi: <https://doi.org/10.1590/s1676-24442002000400011>
4. Amin S, Findeis SK, Whiteley A, et al. An unusual presentation of an uncommon lymphoma, hepatosplenic T-cell lymphoma. *Proc (Bayl Univ Med Cent).* 2019;32(1):129-30. doi: <https://doi.org/10.1080/08998280.2018.1509592>
5. Myoteri D, Dellaportas D, Ayiomamitis G, et al. Erratum to "Primary angiosarcoma of the spleen: an oncological enigma." *Case Rep Oncol Med.* 2019;2019:5605401. doi: <https://doi.org/10.1155/2019/5605401>
6. Werner B, Campos AC, Nadji M, et al. Uso prático da imuno-histoquímica em patologia cirúrgica. *J Bras Patol Med Lab.* 2005;41(5):353-64. doi: <https://doi.org/10.1590/s1676-24442005000500011>
7. Bascuas T, Moreno M, Mónaco A, et al. A novel non-Hodgkin lymphoma murine model closer to the standard clinical scenario. *J Transl Med.* 2016;14(1):323. doi: <https://doi.org/10.1186/s12967-016-1073-8>
8. Martínez A, Martínez-Ramírez M, Martínez-Caballero D, et al. Radioinmunoterapia en el linfoma no Hodgkin, posicionamiento, seguridad y eficacia de 90Y-ibritumomab. Experiencia y seguimiento a los 10 años. *Rev Esp Med Nucl Imagen Mol.* 2017;36(1):13-9. doi: <https://doi.org/10.1016/j.remnm.2016.05.004>
9. Baena-Gómez MA, Matilla MM, Atienza AL, et al. Linfoma no Hodgkin: excelentes resultados a expensas de elevada toxicidad del tratamiento. *An Pediatr.* 2015;82(6):381-7. doi: <https://doi.org/10.1016/j.anpedi.2014.09.005>
10. Oliveira LC, Fardilha C, Louro M, et al. Palliative splenic irradiation for symptomatic splenomegaly in non-Hodgkin lymphoma. *Ecancermedicalscience.* 2018;12:887. doi: <https://doi.org/10.3332/ecancer.2018.887>

Recebido em 3/2/2021  
Aprovado em 19/3/2021