

# Splenic haemangioma and Kasabach-Merritt Syndrome as differential diagnosis for abdominal mass in a newborn: case report

*Hemangioma esplênico e Síndrome de Kasabach-Merritt como diagnóstico diferencial de massa abdominal do recém-nascido*

RVW Bach,<sup>1</sup> RV Carvalho,<sup>2</sup> PAS Faria,<sup>3</sup> AR Gonçalves<sup>4</sup> e CHV Mariño<sup>2</sup>

## Abstract

We report a rare case of splenic haemangioma in the form of an abdominal mass in a 20-day-old female newborn with coagulopathy and thrombocytopenia. She was operated on, and the mass was found to be a tumor of the inferior pole of the spleen. She remains well after six months of follow-up. The diagnostic and treatment options are reviewed and discussed. The authors reviewed the literature about splenic haemangioma in newborns, noticing that it is the third reported case associating splenic haemangioma and Kasabach-Merritt Syndrome. Splenic haemangioma is a rare differential diagnosis to abdominal masses in newborns. Haemangioma is the most frequent benign neoplasm of the spleen. Anemia, thrombocytopenia and coagulopathy are often found in patients with large cavernous haemangioma associated with Kasabach-Merritt syndrome (KMS). The development of splenic haemangiomas in that syndrome is extremely rare in newborns.

**Key words:** hemangioma; splenic neoplasms; abdominal masses; newborn tumors; therapy; diagnostic; newborn infant.

---

<sup>1</sup>Pós-graduando da Seção de Cirurgia Pediátrica. Instituto Nacional de Câncer, Hospital do Câncer I, Rio de Janeiro, RJ - Brasil.

<sup>2</sup>Médico Cirurgião Pediátrico da Seção de Cirurgia Pediátrica. Instituto Nacional de Câncer, Hospital do Câncer I, Rio de Janeiro, RJ - Brasil.

<sup>3</sup>Médico Patologista da Seção de Anatomopatologia. Instituto Nacional de Câncer, Hospital do Câncer I, Rio de Janeiro, RJ - Brasil.

<sup>4</sup>Médico Cirurgião Pediátrico, Chefe da Seção de Cirurgia Pediátrica. Instituto Nacional de Câncer, Hospital do Câncer I, Rio de Janeiro, RJ - Brasil. *Enviar correspondência para A.R.G. E-mail: albertog@inca.org.br*

*Recebido em maio de 2001*

## Resumo

*Apresentamos um caso raro de hemangioma esplênico em um recém-nascido do sexo feminino, apresentando-se como massa abdominal, coagulopatia e trombocitopenia. No ato operatório observou-se uma massa tumoral vascular do pólo inferior do baço. A paciente encontra-se em acompanhamento ambulatorial. O diagnóstico e as opções de tratamento foram revistas e discutidas. Os autores revisaram a literatura sobre hemangioma esplênico em recém-nascidos e observaram ser este o terceiro caso de associação entre hemangioma esplênico e síndrome de Kasabach-Merritt. O hemangioma esplênico é uma doença rara no diagnóstico diferencial das massas abdominais em recém-nascidos. O hemangioma é a neoplasia benigna mais freqüente do baço. A anemia, a trombocitopenia e a coagulopatia são vistos com freqüência em hemangiomas cavernosos grandes associados à Síndrome de Kasabach-Merritt (KMS). O hemangioma cavernoso esplênico associado com esta síndrome é extremamente raro.*

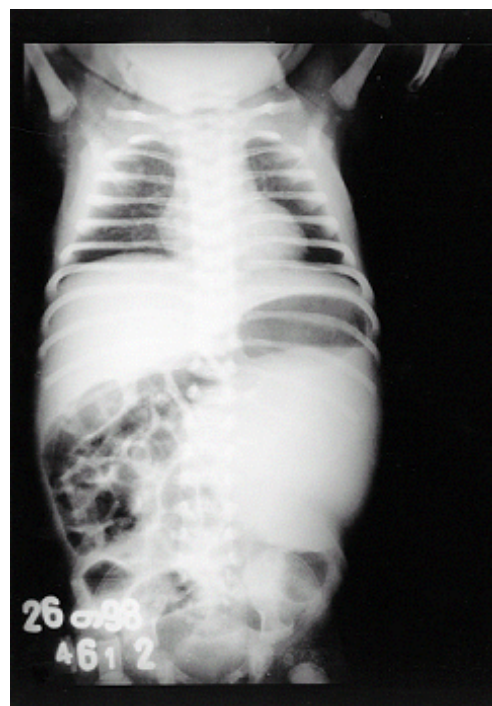**Palavras-chave:** *hemangioma; neoplasias esplênicas; massas abdominais; tumores neonatais; terapia; diagnóstico; recém-nascido.*

## CASE REPORT

A 20-day-old female newborn had bilious vomiting since birth. She had low weight and presented a solid abdominal mass in the left flank, anemia (hematocrit of 25.5%) and thrombocytopenia (66,000 of platelet counting). Plain thoraco-abdominal radiography (Figure 1) and an abdominal ultrasound examination were performed, as well as an abdominal computerized tomography (Figure 2), that showed a solid heterogeneous mass in left flank. Serum tumoral markers were negative for beta-human-coriolic-gonadotropin, alpha-fetoprotein, vanilmandelic and homovanilic acid. Serum metabolic studies, liver laboratory testing, and complete screening for coagulopathy were normal, as well as a mielogram.

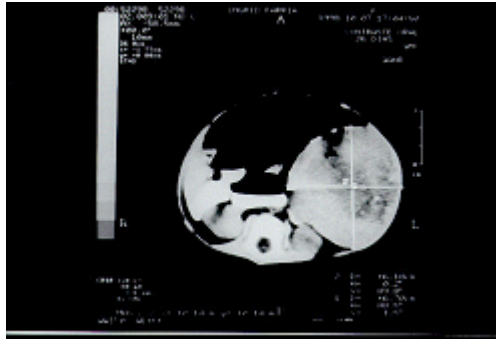
The newborn was operated on and it was found an angiomatous tumor in the inferior pole of the spleen, vascularized by a branch of the splenic artery. The tumor was resected after clipping of the nutritious artery. The reminiscent spleen persisted to bleed, and after some attempts to stop the bleeding, it was resected. There was an accessory spleen on the large omentum, so we did not have to make heterotopic autotransplantation.

Figure 1. Plain thoraco abdominal radiography showing the large left flank mass.



The first specimen weighed 126g, and showed a 7.5 x 5.5 x 5cm round reddish tumor with irregular yellow firm central area (Figure 3). Microscopically the lesion consisted of small capillary sized spaces with red blood cells in their lumen (Figure 4). The central yellow area showed sclerosis. The residual spleen was 3.5 x 2.5 x 2cm in size, and showed no abnormalities.


Figure 2. Abdominal Computed Tomographic examination.



Pathology examination revealed it was a cavernous haemangioma of the spleen. The patient remains well after surgery, and the platelet counting was normal. The patient was followed-up for six months until now. She is gaining weight and remains well.

Haemangioma is the most frequent neoplasm of the spleen, although it is very rare.<sup>1,2</sup> Only one out of 348 surgically removed spleens presented a primary haemangioma.<sup>3</sup> Symptomatic haemangioma is even rarer. We found only 22 previous cases in children, some of them presenting just similar pathologic studies (angioma, haemangi endothelioma, and haemangihamartoma).<sup>2,4-9</sup> Only four out of those 22 were newborns, two presented with haemangioma, two presented with haemangi endothelioma.<sup>2,4,6,9</sup>

Figure 3. Cross-sectional aspect of the surgical specimen.



Splenic or hepatic haemangioma are often associated with Kasabach-Merritt Syndrome (KMS), although this syndrome is more frequent in cutaneous haemangioma.<sup>7</sup> This is the third case of splenic haemangioma associated with KMS in newborns reported in the literature (researched on the PubMed Archives of the National Library of Medicine

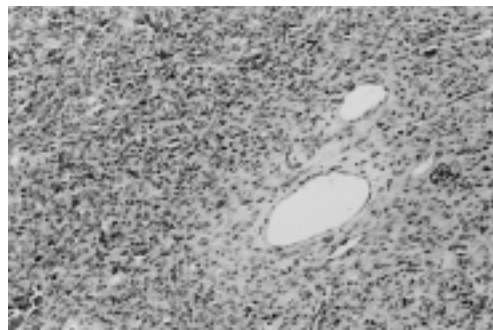
until 2001, October). The very first case was that of Sencer et al.<sup>7</sup> who reviewed other 14 similar cases of large splenic haemangioma in children, median age of 4,9 years, some of them pathologically unconfirmed. Bravo et al<sup>4</sup> reported another case. There are two cases of splenic haemangi endothelioma in newborns,<sup>6,9</sup> one of them ruptured,<sup>6</sup> but none related to KMS.

Splenic haemangioma grows slowly, presenting late in adulthood. Symptoms are upper left abdominal pain and mass. Spontaneous rupture may occur in up to 25% of the cases, but they are uncommon in newborns.<sup>1</sup> Splenic haemangioma may be part of systemic haemangiomas.<sup>10</sup>

Kasabach and Merritt<sup>11</sup> described an association between thrombocytopenia and large haemangioma. Zervos et al<sup>12</sup> reported the first case of splenic haemangioma causing that syndrome.<sup>2</sup> Thrombocytopenia may be secondary to platelet sequestration in the abnormal endothelium of the tumor. There may be even hypofibrinogenemia because of intravascular coagulopathy.<sup>2</sup>

Differential diagnosis to splenic haemangioma must include haemangi endothelioma,<sup>5</sup> splenic littoral cell angioma,<sup>13</sup> hamartoma and fibroangioma.<sup>2</sup> In newborns splenic haemangioma may be differentiated from other solid abdominal tumors.

Figure 4. Histologic aspects of the surgical specimen. One can see the small capillary sized spaces with red blood cells in their lumen.



The histology of haemangioma is characterized by the presence of vascular channels paved with endothelium. At immunohistochemistry studies, the capillary subtype presents with factor-VIII related antigen and CD8-; the diffuse subtype presents with CD68+; all subtypes present with CD34+.<sup>14,15</sup>

The typical images of splenic and hepatic haemangioma at ultrasound, CT-scan, and MRI have been defined for the last 15 years.<sup>16,17</sup> The ultrasound image shows hyperechogenic mass on spleen. Color-Doppler ultrasound allows definitive diagnosis with 84% sensitivity and 98% specificity.<sup>18,19</sup> The CT-scan, firstly without and sequentially with intravenous contrasting, may show a characteristic progressively hyperdense mass,<sup>20</sup> with 61.3% sensitivity for detecting splenic and hepatic haemangioma.<sup>17</sup> Dynamic Gadolinium MRI appears to be the state-of-the-art imaging examination to define splenic haemangioma, typical areas of hypointense radial streaks on T1 and hyperintensity are observed in T2-weighted images correlated precisely with the pathological findings and differentiate from other splenic tumors.<sup>1</sup>

Other valuable studies are digital subtraction angiography<sup>17</sup> or bone cintigraphy.<sup>21</sup> Aspirative biopsy guided by ultrasound may differentiate benign haemangioma from other malignant neoplasms.<sup>17,22</sup>

Some juvenile haemangioma may respond to prednisone treatment, however it is of limited value when KMS occurs. Tryfonas studied 10 patients with cavernous splenic haemangioma and KMS, treated with alpha-2-interferon (3 MU/m<sup>2</sup>/dose), obtaining total remission on 5/10 patients e partial remission on 5/10 patients.<sup>23</sup> In another three life-threatening cases reported, there was total disappearance of the cutaneous tumor in one patient, and partial remission (60%-80% of the tumors) in the other two patients.<sup>24</sup> There are no reports on the use of alpha-2-interferon for treating visceral haemangioma, but its uses for treating large cutaneous haemangioma on newborn is already established.<sup>25,26</sup>

The treatment of a large splenic haemangioma is the resection of the tumor or total splenectomy when it is impossible to leave some healthy splenic tissue.<sup>2,6</sup> Splenic heterotopic autotransplantation, implanting free splenic residues on the major omentum is viable. If it maintains splenic residual function, it may diminish the risk of sepsis. There is some post-operative testing that may confirm splenic residual function: absence of Howell-Jolly corpuscle, normal serum dosage

of IgM, and abdominal cintigraphy with marked haemata.<sup>4,6,27,28</sup>

## REFERENCES

1. Ramani M, Reinhold C, Semelka RC, Siegelman ES, Liang L, Ascher SM, et al. Splenic hemangiomas and hamartomas: MR imaging characteristics of 28 lesions. *Radiology* 1997;202:166-72.
2. Sencer S, Coulter-Knoff A, Day D, Folker J, Thompson T, Burke B. Splenic hemangioma with thrombocytopenia in a newborn. *Pediatrics* 1987 Jun;79(6):960-6.
3. Simu G, Bancu VE, Macavei I, Fazekas A, Tohati MT. Microscopic patterns in surgically removed spleens. *Rom J Morphol Embryol* 1991 Jan-Jun;37(1-2):81-6.
4. Bravo M, Aldunate G, Las Heras J, Pumarino G. Hemangioma of the spleen in a newborn infant. Postsplenectomy course and splenic autotransplantation. *Rev Chil Pediatr* 1989 Jan-Feb;60(1):40-3.
5. Budke HL, Breitfeld PP, Neiman RS. Functional hyposplenism due to a primary epithelioid hemangi endothelioma of the spleen. *Arch Pathol Lab Med* 1995 Aug;119(8):755-7.
6. Cerda J, Mialdea RL, Soletto J, Martin-Crespo R, Aguilar F. Segmentary splenectomy of the lower tip because of spontaneous rupture of a splenic hemangi endothelioma in a newborn child -a case report. *Eur J Pediatr Surg* 1994 Apr;4(2):113-5.
7. Hoeger PH, Helmke K, Winkler K. Chronic consumption coagulopathy due to an occult splenic hemangioma: Kasabach-Merritt syndrome. *Eur J Pediatr* 1995 May;154(5):365-8.
8. Panuel M, Ternier F, Michel G, et al Splenic hemangioma: report of three pediatric cases with patologic correlation. *Pediatr Radiol* 1992;22(3):213-6.
9. Wu CC. Neonatal hepatic hemangi endothelioma identified by real-time ultrasound: report of a case. *J Formos Med Assoc* 1990 Oct;89(10):909-12.
10. Dixit VK, Sharma H, Ratnakar KS, Murthy VS. Splenic hemangiomas with osseous involvement. *Indian J Gastroenterol* 1993 Jul;12(3):105-6.
11. Kasabach HH, Merritt KK. Capillary hemangioma with extensive purpura. *Am J Dis Child* 1940;59:1063-70.

12. Zervos N, Vlachos J, Karpathios E, Mantas J. Giant hemangioma of the spleen with thrombocytopenia and fibrinogen deficiency. *Acta Paediatr Scand* 1967;172(Suppl):206-9.
13. Falk S, Stutte HJ, Frizzera G. Litoral cell angioma: a novel splenic vascular lesion demonstrating histiocytic differentiation. *Am J Surg Pathol* 1991 Nov;15(11):1023-33.
14. Arder DA, Strickler JG, Chen YY, Weiss LM. Splenic vascular tumors: a histologic, immunophenotypic, and virologic study. *Am J Surg Pathol* 1997 Jul;21(7):827-35.
15. Zukerberg LR, Kaynor BL, Silverman ML, Harris NL. Splenic hamartoma and capillary hemangioma are distinct entities: immunohistochemical analysis of CD8 expression by endothelial cells. *Hum pathol* 1991 Dec;22(12):1258-61.
16. Hayasaka K, Tanaka Y, Kawamori J. Dynamic MR imaging of splenic tumor. *Comput Med Imaging Graph* 1997 Jul-Aug;21(4):243-51.
17. Velkova K, Nedeva A. Our experience in the diagnosis of liver and spleen hemangiomas. *Folia Med (Plovdiv)* 1997;39(1):85-91.
18. Dubois J, Patriquin HB, Garel L, Powell J, Filiatrault D, David M, et al. Soft-tissue hemangiomas in infants and children: diagnosis using Doppler sonography. *AJR* 1998 Jul;171(1):247-52.
19. Goerg C, Schwerek WB. Color Doppler imaging of focal splenic masses. *Eur J Radiol* 1994 Aug;18(3):214-9.
20. Bail JP, Menut P, Andivot T, Leal T, Volant A, Charles JF. Cavernous hemangioma of the spleen: values and limitations of ultrasonic and computed tomography diagnosis. *Ann Chi* 1994;48(4):370-3.
21. Katz DS, Wojtowycz AR, Markarian B. Splenic hemangioma: detection on a technetium-99M MDP bone scan. *Clin Imaging* 1994 Oct-Dec;18(4):279-82.
22. Barbazza R, De Martini A, Mognol M, Banzi A, D'Agata G. Fine needle aspiration biopsy of a splenic hemangioma: a case report with review of the literature. *Haemathologica* 1990 May-Jun;75(3):278-81.
23. Tryfonas GI, Tsikopoulos G, Liasidou E, Gavapoulos S, Georgakis G, Badouraki M, et al. Conservative treatment of hemangiomas in infancy and childhood with interferon-alpha-2a. *Pediatr Surg Int* 1998 Oct;13(8):590-3.
24. Sarihan H, Mocan H, Abeys M, Akyazici R, Cay A, Imamoglu M. Kasabach-Merritt syndrome in infants. *Panminerva Med* 1998 Jun;40(2):128-31.
25. Castello MA, Ragni G, Antimi A, Todini A, Patti G, Lubrano R, et al. Successful management with interferon alpha-2a after prednisone therapy failure in an infant with a giant cavernous hemangioma. *Med Pediatr Oncol* 1997 Mar;28(3):213-5.
26. Nako Y, Fukushima N, Igarashi T, Hoshino M, Sugiyama M, Tomomasa T, et al. Successful interferon therapy in a neonate with life-threatening Kasabach-Merritt syndrome. *J Perinatol* 1997 May-Jun;17(3):244-7.
27. Revuelta Alvarez S, Fernandez-Escalante C, Casanova Rituerto D, Lopez Espadas F, Martin Fernandes, Martin Fernandez I. Assesment of post splenectomy residual splenic function. Splenic autotransplants. *Int Surg* 1987 Jul-Sep;72(3):149-53.
28. Yamataka A, Fujiwara T, Tsuchioka T, Kurosu Y, Sunagawa M. Heterotopic splenic autotransplantation in a neonate with splenic rupture, leading to normal splenic function. *J Pediatr Surg* 1996 Feb;31(2):239-40.