

27

Primary Malignant Mucosal Melanoma of the Esophagus. A Case Report*

COSIMO LEQUAGLIE¹, MARCO ALLOISIO¹, MAURO ONGARI¹, CLAUDIO LUIZ VIEGAS²,
SALVATORE ANDREOLA³, GIANLUIGI RAVASI⁴,

Summary

Primary malignant melanoma is a rare lesion, that accounts for only 0.1% of primary esophageal malignant neoplasms.

The tumor is polypoid, pedunculated and sometimes ulcerated. Symptoms are similar to those of squamous cell carcinoma and the preoperative differential diagnosis is important. Surgical resection is the treatment of choice. Intracavitary radiotherapy may be a useful form of adjuvant therapy in selected patients.

Here we record the case of a 67 years old man with a primary malignant melanoma of the esophagus. He underwent an esophagectomy, and is still alive 5 months after the procedure.

Uniterms: primary malignant melanoma, esophagus.

Introduction

Primary malignant melanoma of the esophagus is a rare malignant lesion, accounting for 0.1% of primary malignant neoplasms¹³. In 1906 Baur gave the first report about this³; since this period no more than 115 cases have been found in the world literature^{1, 4, 7, 8, 12}.

We have recently been able to add a case of our own which is now presented in the following report. Moreover, we have collected updated information about clinical features, diagnosis, management and natural history of this unfrequent esophageal tumor.

Case report

A 62-year-old white man, manager, smoking 25 cigarettes a day since he was 17, no alcoholic history, was initially admitted to a peripheric hospital. His complaint was that for 2 months he had had difficulty in swallowing solid food (sometimes also in swallowing fluids), but he had not suffered weight loss neither odinophagia or retrosternal pain.

Forty years before the patient had had an appendicectomy and 30 years before a gastric resection sec. Billroth II for peptic ulcer. One year before he had his left eye cataract removed.

A barium swallow esophagram revealed a 5cm polypoid and ulcerated mass, in the middle esophagus (Figure 1). Fiberoptic endoscopy also revealed the presence of a polypoid, necrotic, ulcerated mass 30cm from the incisor teeth and extending to 35cm.

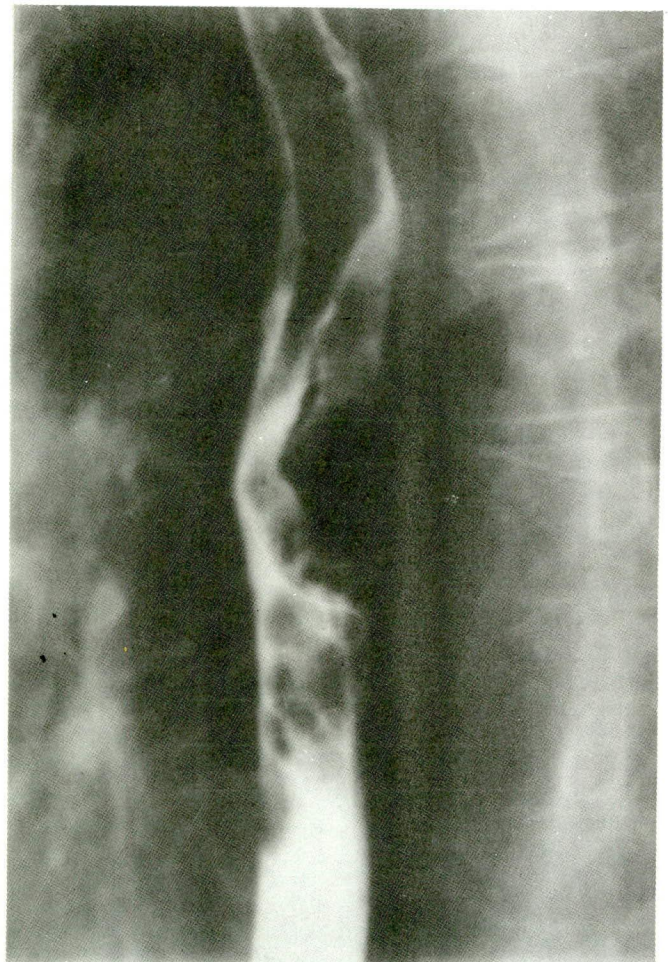


Figure 1 — Esophagram shows a polypoid and ulcerated mass in the mid-esophagus.

*From the Department of Thoracic Surgery, Istituto Nazionale per lo Studio e la Cura dei Tumori, via Venezian 1, 20133 Milan, Italy. ¹Assistant of Surgery, Istituto Nazionale Tumori, Milan, Italy. ²Scholar sponsored by CNPq (Conselho Nacional de Desenvolvimento Científico e Tecnológico), Brasil. ³Assistant Pathologist, Istituto Nazionale Tumori, Milan, Italy. ⁴Chief of Thoracic Surgery, Istituto Nazionale Tumori, Milan, Italy.

Biopsies of the neoplasm were interpreted as showing an anaplastic malignant tumor involving the submucosa of the esophagus. Brushings showed a +++ for presence of malignant tumoral cells.

Hematology and liver-function tests showed normal indexes. Liver scan and chest x-ray did not reveal images of metastases or other diseases. The patient was referred, on July 22, 1986, to our Division of Oncologic Thoracic Surgery.

Results of physical examination on admission revealed a well developed and nourished man. A more careful examination did not show lesions that suggested melanoma of the skin or in other sites (eyes, ears, nose, anal mucosa).

Bronchoscopy revealed a normal tracheobronchial tree. A CT scan from the jugulum to the lower hepatic border showed no local spread, nor metastases in the lungs and in nodes, neither in the upper abdominal and retroperitoneal regions; it only revealed a thickening of the esophageal wall and a round polypoid mass endoluminal back located in the mid-esophagus (Figure 2).

The cardio-respiratory status was well-examined and did not reveal abnormalities.

Operation was performed on July 28, 1986. The abdomen was explored through a midline supra-umbilical incision. No metastases were detected. It was a hydrocholecystitis with many little stones, so a cholecystectomy was performed. The transverse colon was mobilized and resected. The mid-colon artery was preserved. The left gastric artery was cut and a nodes dissection was made. The esophagus was mobilized sec. Oringer by blunt dissection without thoracotomy, cutting the phrenoesophageal ligament. Afterwards a cervicotomy on the right side was performed. An end-to-end anastomosis colo-colic was performed by ILS 29 disposable + LS 30. The stapler device was strengthened by Maxon 000. The esophagus was resected by GIA x 1 at cardia level and by scissors at cervical level under pharyngeal constrictor. An end-to-lateral anastomosis colo-gastric was performed by ILS 29 + LS 30 on the jejunotomy and made stronger by Maxon 000. The transverse colon was located in esophageal site in antiperistaltic version. And finally, an end-to-lateral anastomosis pharyngo-colic was performed by ILS 21 and Maxon 000 in double layer. There were no problems. Two drainages were positioned: one of them, near anas-

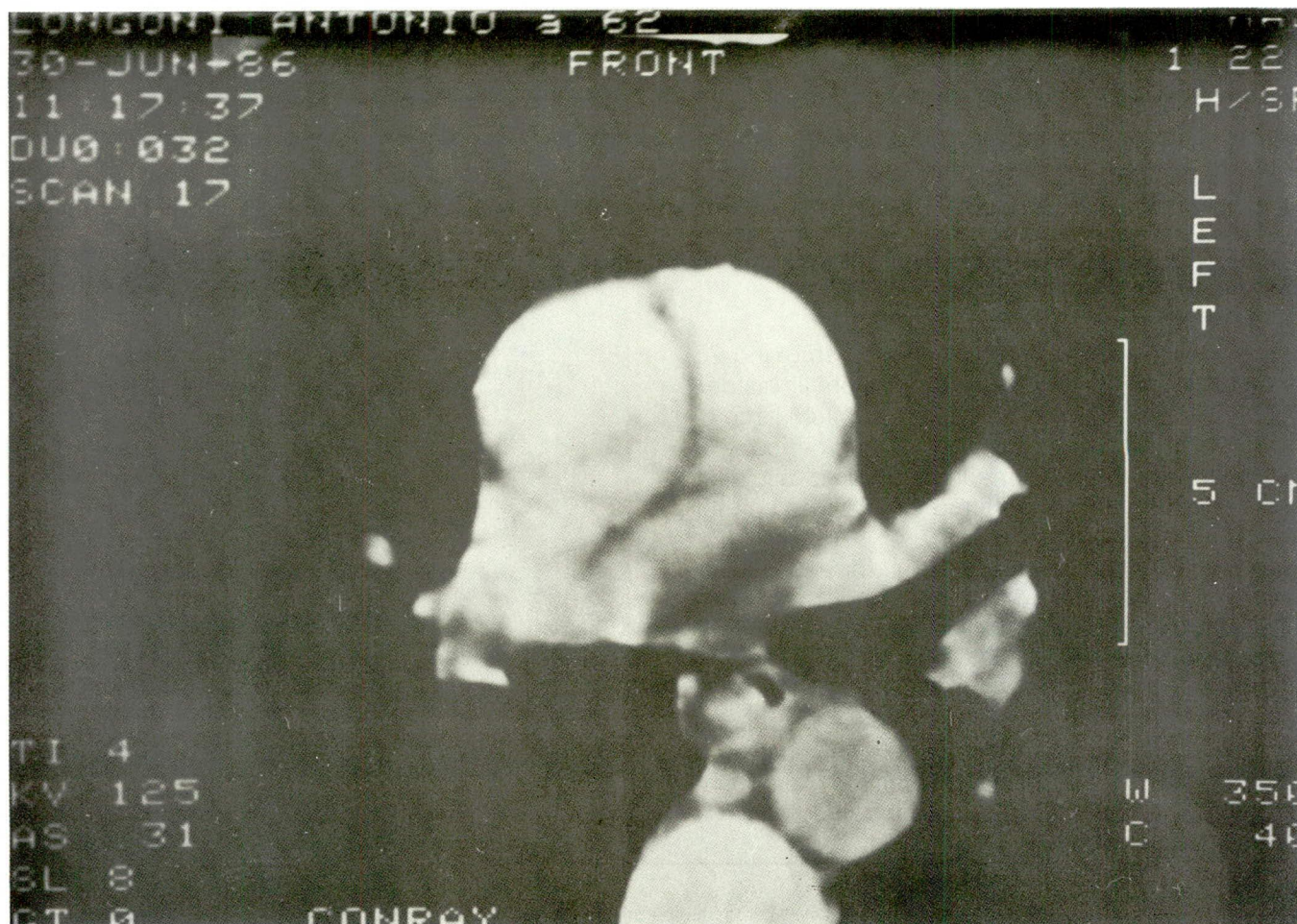


Figure 2 — CT scan reveals a thickening of the esophageal wall and a round polypoid mass endoluminal back located in the mid-esophagus.

tomosis, at cervical level, the other one abdominal crossing the hiatus oesophageus up to left pleural cavity.

Surgical palpation revealed two tumors of the esophagus and no evidence of tearings of the esophageal wall.

Numerous specimens from the two neoplasms were fixed in 10% formalin and paraffin embedded. Sections were cut at 5 microns stained with hematoxylin-eosin and immunohistochemically with an anti-S100 protein serum (Dakopatts, Santa Barbara, CA, USA), dilution 1:400, using the avidin-biotin complex immunoperoxidase technique (ABC).

The specimen consisted of 15cm of the esophagus with two distinct neoplasms (Figure 3). The first tumor was located at 5cm from the nearest margin of resection and was a polypoid, ulcerated, soft mass measuring 5 x 3.5cm. The cut surface was grayish-white with no evidence of necrosis and hemorrhage. The second tumor was 1.5cm distant from the first; it measured 1.2cm in diameter and had macroscopic features similar to the larger one. Microscopically the tumors were similar. They were composed of large, polygonal cells. The cytoplasm was moderate to abundant in amount

and intensely eosinophilic. Nuclei were large, ovoid with irregular clumps of chromatin peripherally located and prominent eosinophilic nucleoli. The majority of the cells were no-pigmented and only a few intracytoplasmic melanin granules were found in the cells of the smaller tumor. In the esophageal epidermal-connective tissue junction overlying the larger tumor there was a conspicuous atypical melanocytic proliferation (Figure 4). This was made up of either single cells or large nests of atypical melanocytes which protruded through the surface epithelium. The upper surface of the small tumor was totally ulcerated and no junctional activity could be demonstrated. Neoplastic cells were focally but intensely reactive with the anti-S100 protein serum (Figure 5). The histology of the recurrent right lymph node was similar to the esophageal tumor and was considered metastatic. The margins of resection were free of tumor.

Contrast radiography postoperatively showed free passage through the cologastric anastomosis (Figure 6).

A bilateral pneumonia complicated the postoperative course. The patient left the hospital on the 20th day after surgery.

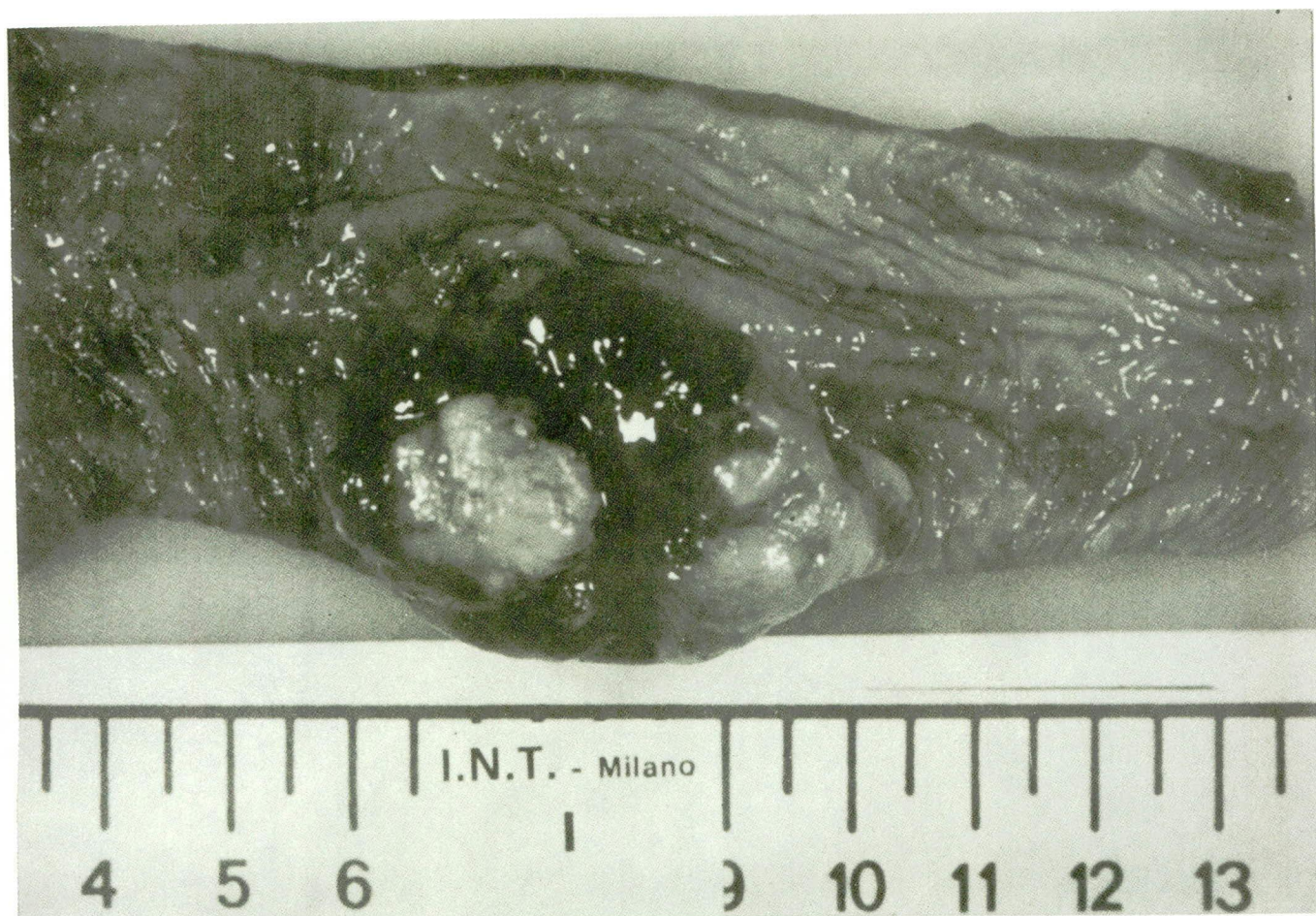

Figure 3 — Surgical specimen of the esophagus shows two polypoid, ulcerated and soft masses. Microscopically they were malignant melanoma.

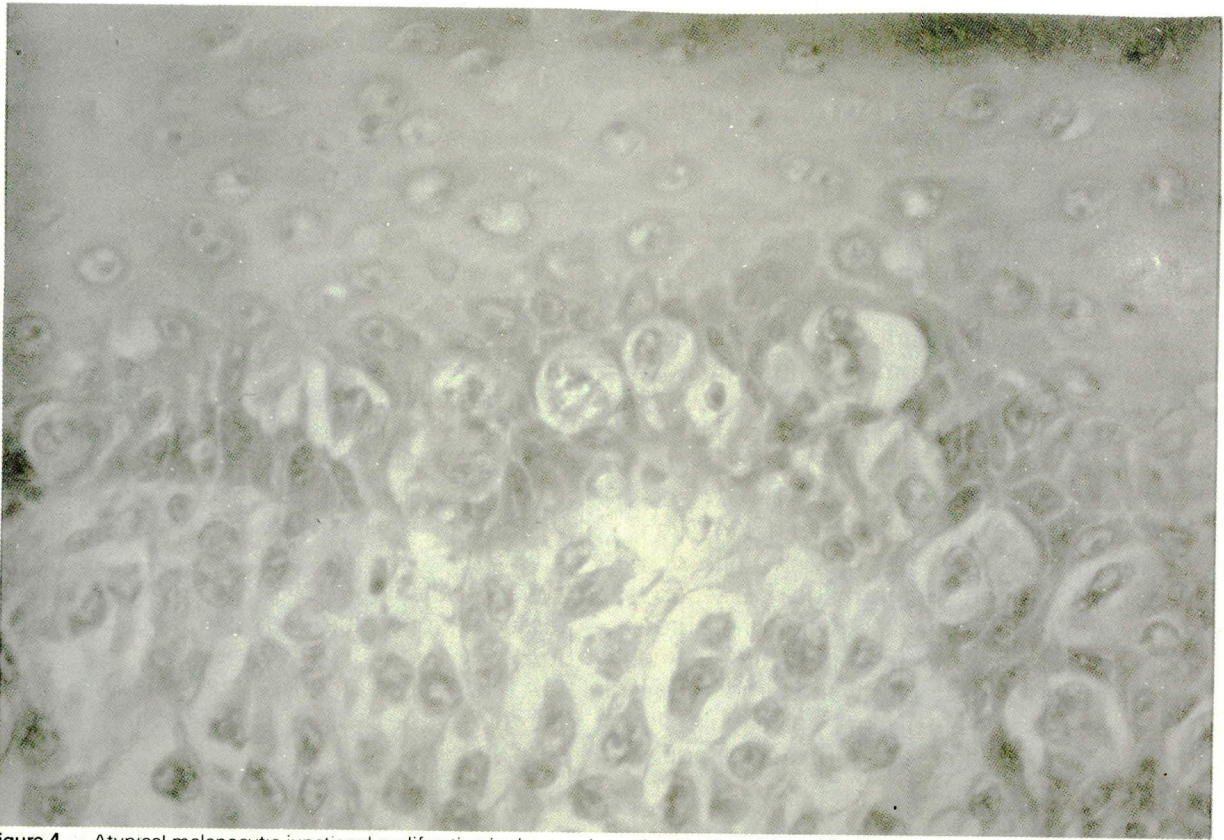


Figure 4 – Atypical melanocytic junctional proliferation in the esophageal epithelium. (H. and E. 400x).

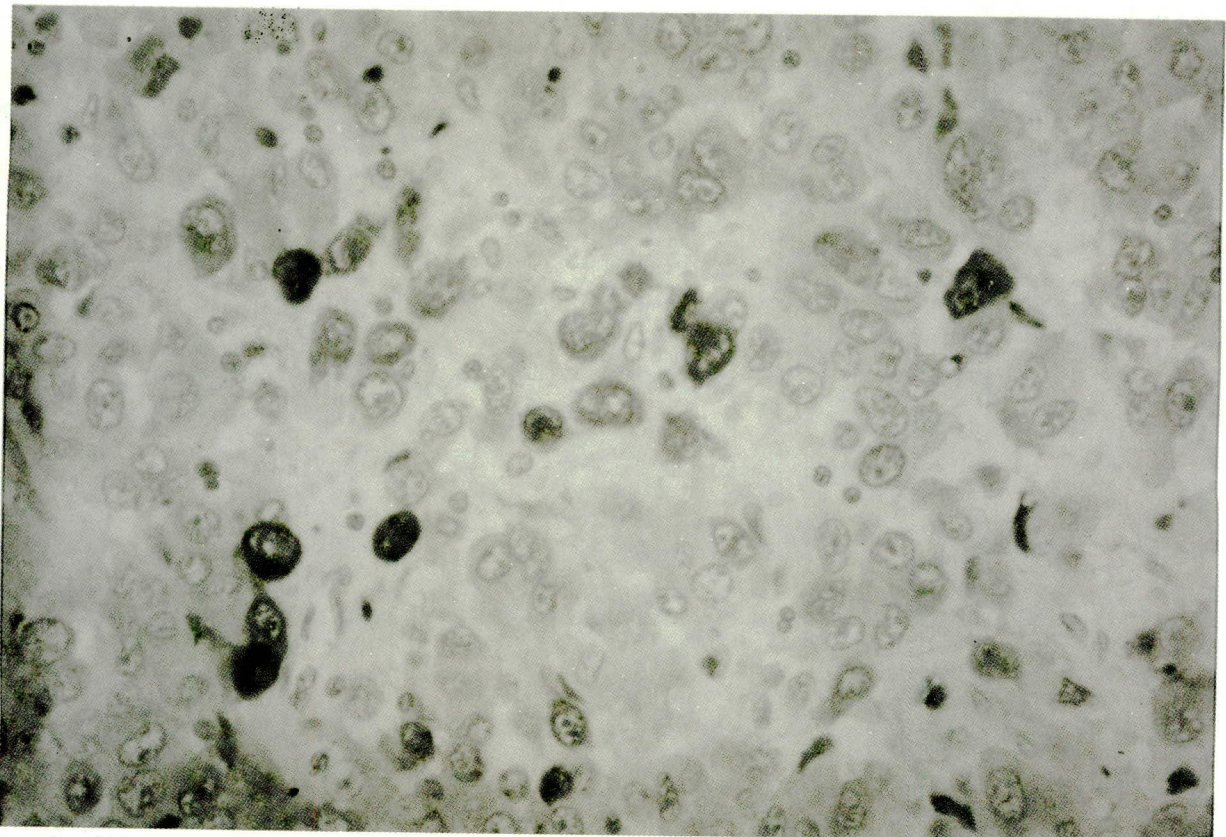


Figure 5 – Melanoma cells intensely reactive with the anti-S100 protein serum. (400x).

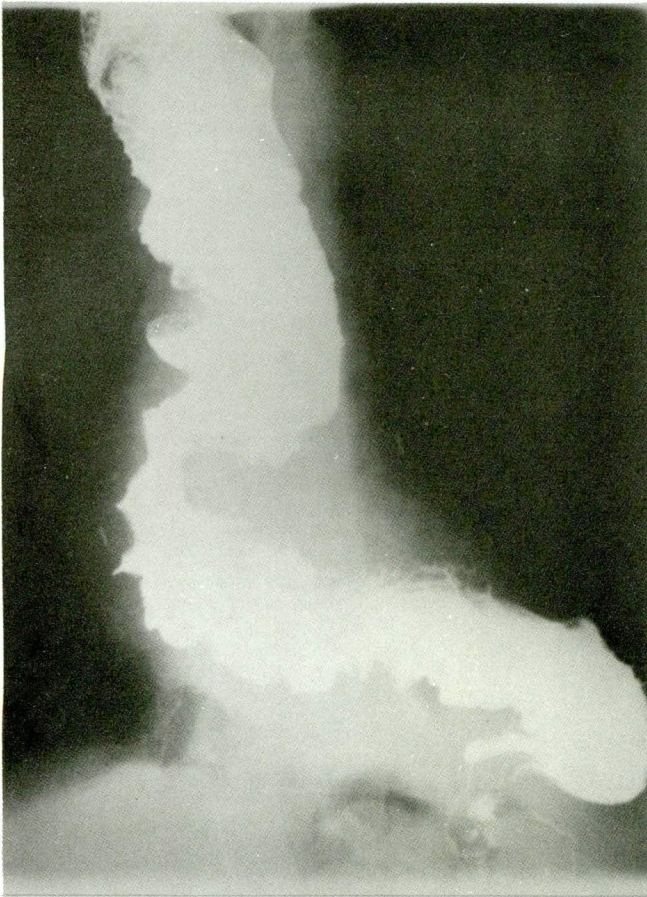

Figure 6 — Contrast radiography postoperatively shows free passage through the cologastric anastomosis.

Regurgitation appeared 3 months later: contrast radiography showed a benign stenosis of the cologastric anastomosis (5mm), confirmed also by endoscopy. The biopsies of the stenotic area did not show a neoplastic recurrence. The liver scan was normal. A control CT scan (thorax, upper abdomen) revealed only a dolichocolon in thorax but no nodes or metastasis in other sites.

On November 6, 1986, the abdomen was explored. A cicatricial stricture of the esophageal hiatus was seen and so a new latero-lateral anastomosis cologastric was performed by hand.

No morbidity or morbidity was related to the second procedure.

Five months after removal of the melanoma the patient has no clinical or roentgenographic signs of metastasis.

Discussion

Malignant mucosal melanoma of the esophagus is a rare tumor representing less than 0.1% of all esophageal malignancies in world literature (0.06% of our own cases).

The existence of a primary malignant melanoma was doubted until the demonstration by De la Pava of melanocytes in esophageal mucosa in 4 of 100 non-selected autopsies⁵.

The diagnosis of primary malignant melanoma should be based on the diagnostic criteria set up by Allen and Spitz: 1) characteristic structure of melanoma containing melanin, 2) the adjacent epithelium contains melanocytes, 3) the tumor is polypoid, and 4) it arises from an area of junctional changes in the squamous epithelium². However, the epithelium over the tumor may be ulcerated (like our case) and so a direct origin from junction epithelium may not be detectable^{6, 11}. We believe that our case represents a true primary malignant mucosal melanoma of the esophagus.

Grossly the tumor appears like a polypoid, large, necrotic and sometimes focally ulcerated mass, but it is mostly covered by normal squamous mucosa. It may be pigmented or not^{4, 6, 9, 10, 11, 14}.

The male to female ratio is 2:1. The youngest patient was 7 years old, and the oldest was 82 years old¹⁴.

Its more frequent site is the lower third of the esophagus, the symptoms are common at the squamous cell carcinoma: dysphagia, retrosternal pain, weight loss, regurgitation, and so on.

The barium swallow esophagram is helpful but often not specific: it shows a large filling defect in the esophagus, and so a polypoid and irregular intraluminal mass. Esophagoscopy reveals a polypoid, sometimes ulcerated, not always pigmented mass. Biopsy may be ineffective and misleading; Kyösala suggests fine-needle aspiration biopsies in preference to conventional biopsies⁷.

The CT and MNR should help to define the regional spread of the tumor and the metastatic nodes.

Hematogenic and lymphogenic metastasis is common. Metastasis to the liver is frequent, 31% of 115 cases in literature, to the mediastinum and mediastinal lymph nodes, 29%, to the lungs, 18%; in 22.3% of patients no metastasis was found^{1, 6, 8, 14}.

Many patients in the literature only received a symptomatic treatment (31%).

Bingham was the first surgeon who performed a colon transplant in malignant melanoma of the esophagus⁹. Some authors suggest lymph node dissection in addition to such procedure⁹.

Postoperative radiation and chemotherapy were used in 8% and 1.5% respectively^{6, 9, 14}. Postoperative radiation may be an adjunctive therapy in patients at high risk for recurrence¹³.

According to reports in the literature^{9, 10}, the prognosis is poor without surgical treatment and so resection of the tumor with an anastomotic procedure is the best treatment in operable patients with primary malignant melanoma of the esophagus.

Resumo

O melanoma maligno primário é uma rara lesão que só compreende cerca de 0,1% das neoplasias malignas primárias de esôfago.

O tumor é polipóide, pedunculado, e algumas vezes ulcerado. Os sintomas se assemelham aos de portadores de carcinomas de células escamosas, tornando-se importante o diagnóstico diferencial pré-operatório. A ressecção cirúrgica é o tratamento de escolha. Radioterapia intracavitária pode ser uma forma útil de tratamento em pacientes selecionados.

Relatamos o caso de um homem de 67 anos, portador de melanoma maligno primário de esôfago, que sobreviveu ainda cinco meses após submeter-se à esofagectomia.

Unitermos: melanoma maligno primário; esôfago

Bibliographic References

1. Aldovini D, Detassis C, Pisciolli F — Primary malignant melanoma of the esophagus. Brush cytology and histogenesis. Acta Cytol (Baltimore) 1983; 27:65-68.
2. Allen AC, Spitz S — Malignant melanoma, a clinicopathologic analysis of the criteria for diagnosis and prognosis. Cancer 1953; 6:1-45.
3. Baur E — Ein fall von primären melanom des oesophagus. Arb Geb Path Anat Inst. zu Tübingen 1906; 5:343-354.
4. Chalkiadakis G, Wihlm JM, Morand G, Weill-Bousson M, Witz JP — Primary malignant melanoma of the esophagus. Ann Thorac Surg 1985; 472-475.
5. De la Pava S, Nigogosyan G, Pickren JW, Cabrera A — Melanosis of the esophagus. Cancer 1963; 16:48-50.
6. Jawalekar K, Treter P — Primary malignant melanoma of the esophagus: Report of two cases. J Surg Oncol 1979; 12:19-25.
7. Kyösola K, Harjula A, Heikkinen L, Timonen T, Miettinen M — Primary malignant melanoma of the esophagus, a case report. Scand J Thor Cardiovasc Surg 1984; 18:267-270.
8. Lautz HU, Schmidt FW, Cullen P — Primary malignant melanoma of the esophagus. Endoscopy 1986; 18:240-242.
9. Ludwig ME, Shaw R, de Suto-Nagy G — Primary malignant melanoma of the esophagus. Cancer 1981; 48:2528-2534.
10. Piccone VA, Klopstock R, Le Veen HH, Sika J — Primary malignant melanoma of the esophagus associated with melanosis of the entire esophagus. First case report. J Thorac Cardiovasc Surg 1970; 59:864-870.
11. Raven RW, Dawson I — Malignant melanoma of the esophagus. Brit J Surg 1964; 51:551-555.
12. Roesch W, Rohener HG — Primary malignant melanoma of the esophagus. Endoscopy 1984; 16:186-188.
13. Turnbull AD, Rosen P, Goodner JT, Beattie EJ — Primary malignant tumors of the esophagus other than typical epidermoid carcinoma. Ann Thorac Surg 1973; 15:463-473.
14. Urbano U, Fornaciari G — Caratteri del melanoma maligno primitivo dell'esofago con presentazione di un caso. Tumori 1975; 61:163-172.