

Imaging in Testicular Tumors

FARZIN EFTEKHARI, M.D.¹, BAO-SHAN JING, M.D.¹, SIDNEY WALLACE, M.D.¹

Uniterms: testicular tumors; imaging in testicular tumors

SECTION I: INTRODUCTION AND ANATOMIC CONSIDERATIONS

Introduction

Prior to the advent of the newer imaging modalities, non-invasive evaluation of scrotal masses was limited to palpation and transillumination. Lymphangiography, however, has long been used in the evaluation of nodal metastases from testicular tumors and remains one of the most informative techniques in the staging of these tumors. More recently, newer non-invasive modalities, such as ultrasonography and computed tomography have become available and have had significant impact on our evaluation. It is the purpose of this article to describe and discuss the relative roles of these imaging modalities in the diagnosis of testicular neoplasms and work-up of metastatic disease. The ultimate role of MRI has yet to be evaluated. Other imaging modalities such as chest radiography, radionuclide scanning, and brain CT scanning may be performed as the need arises. Special procedures such as arteriography and venography are occasionally performed in search of undescended testicles complicated by malignancy.

Imaging techniques are also employed in preparation for transcatheter management by intraarterial infusion of chemotherapy and chemoembolization. In addition, imaging guided percutaneous biopsy and drainage techniques are of considerable value in diagnosis and treatment.

It is assumed that the reader is aware of the WHO classification shown on Table 1¹ and also of the multipotential nature of the germ cell tumors (Figure 1)².

Table 1 — W.H.O. pathologic classification testicular tumors

I. Germ Cell Tumor
A. Tumors of one histologic type
1. Seminoma
2. Spermatocytic seminoma
3. Embryonal carcinoma
4. Yolk sac tumor (embryonal carcinoma infantile type)
5. Polyembryoma
6. Choriocarcinoma
7. Teratomas
a. Mature
b. Immature
c. With malignant transformation
B. Tumors with > 1 histologic pattern
1. Embryonal carcinoma + teratoma (teratocarcinoma)
2. Choriocarcinoma and any other types (specify)
3. Other combinations (specify)
II. Sex Cord-Stroma Tumors
A. Well-differentiated forms
1. Leydig cell tumor
2. Sertoli cell tumor
3. Granulosa cell tumor
B. Mixed forms (specify)
C. Incompletely differentiated forms

The classification most commonly employed at M.D. Anderson Hospital is shown on Table 2. Typical spread of testicular tumors is to the retroperitoneal lymph nodes, followed by the supradiaphragmatic mediastinal chain and supraclavicular nodes^{3,4}. The most common extranodal metastases are to the lungs and liver. However, uncommon sites of metastatic disease have also been observed involving organs such as: kidneys,

¹Department of Diagnostic Radiology, The University of Texas M.D. Anderson Hospital and Tumor Institute at Houston, Box 57, 1515 Holcombe Blvd., Houston, Texas 77030. Address all reprint requests and correspondence to: Dr. Farzin Eftekhari, (713) 792-2725.

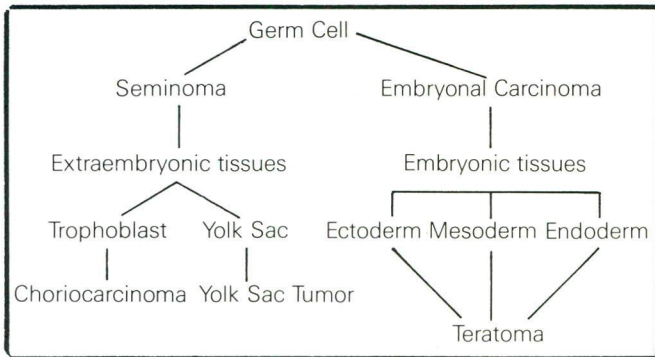


Figure 1 — Histogenesis and multipotential nature of testicular tumors. Adapted from Pierce G.B., Jr. and Abell M.A.: Embryonal Carcinoma of the testis. *In* Sommers S.C. (ed.): Pathology Annual. New York, Appleton-Century-Crofts, 1970, p. 28.

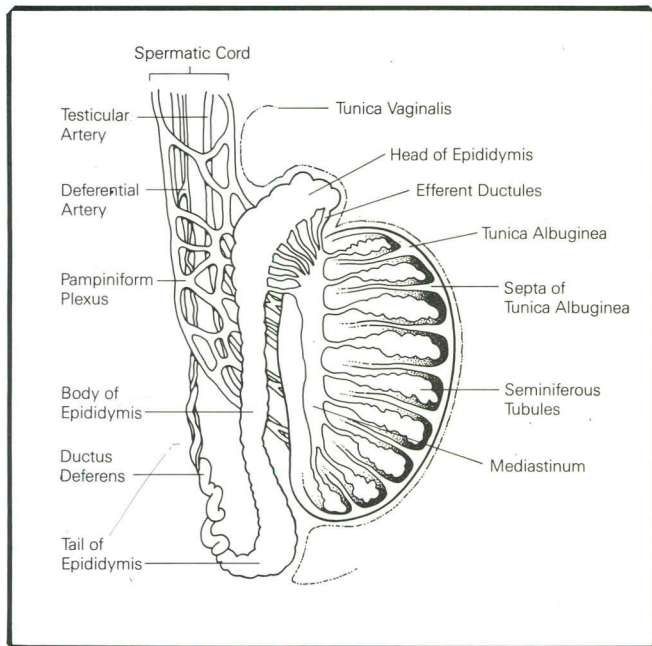


Figure 2 — Anatomy of the scrotum. (From: The Radiologic Clinics of North America 1985; 23 (1): 122, reproduced with permission.)

adrenals, spleen, stomach and even the inferior vena cava³.

Anatomy

The normal testis (Figure 2) is an ovoid gland usually measuring just over 4cm in its longest dimension. The tunica vaginalis, as visceral peritoneum, covers the testis except at its site of attachment to the epididymis and spermatic cord. A capsule, the tunica albuginea, and numerous septa divide the testis into compartments, these converging toward the upper pole of the mediastinum region, which contains the rete testis (Figure 2). Each compartment contains several highly convoluted seminiferous tubules, these converging toward the rete network. Here they connect by straight tubular recti

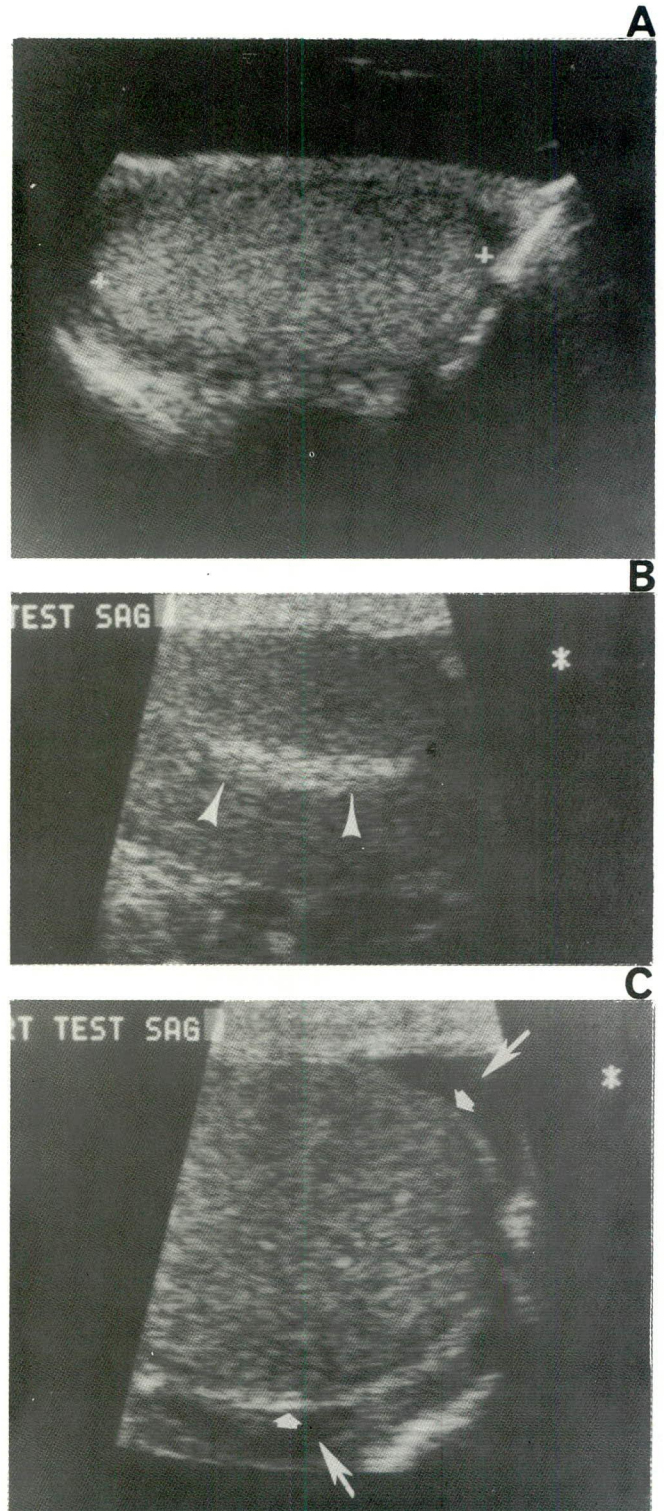


Figure 3 — Sonographic anatomy of the normal testis. A. Sagittal scan demonstrating uniform medium level of echogenicity (cursors). B. Sagittal scan showing echogenic band of the mediastinum testis (arrowheads). C. Sagittal scan showing a normal testis with a small hydrocele (long arrows) enabling visualization of the tunica vaginalis (short arrows).

which join to open into the head of the epididymis. At the upper pole of the testis is the appendix testis, a small vestigial pedunculated or sessile body.

Sonographically, the testis displays a uniform medium level of echogenicity similar to that of the thyroid gland (Figure 3). The head and body of the epididymis are routinely visualized and are as echogenic as the testicle or more so. The mediastinum testis, an invagination of the tunica albuginea into the testicular substance, is visualized as a highly echogenic band parallel to the long axis of the testicle (Figure 3). This should not be confused with an echogenic pathologic process. Occasionally, small echogenic foci may be seen with or without acoustical shadowing and these may represent spermatic granuloma or phleboliths⁵. In the presence of a hydrocele, the appendix testis may be visualized cephalad to the testicle. The various layers of the scrotum itself are indistinguishable and are often seen as a highly echogenic stripe. The tunica vaginalis may be visualized when a hydrocele is present (Figure 3)^{5,6}.

Testicular lymphatics (Figure 4) accompany the internal spermatic artery and vein and terminate in sentinel nodes at the level of L-1/L-2 on the left and L-1/L-3 on the right, slightly lateral to the lumbar nodes. From the right testis there may be direct filling of the right lateral nodes above or below the renal vein, or directly to the left-lateral nodes. Thus, there may be immediate crossover of the right testicular lymphatics to the contralateral nodes (Figure 21), while the left testicular lymphatics only crossover after permeating the sentinel nodes. From the lumbar nodes, continuity of the lymphatic system is usually maintained through the thoracic duct^{7,8}.

The external iliac nodes may occasionally drain the testes and on rare occasions pulmonary metastases of testicular tumors are discovered in the absence of retroperitoneal disease. This is most likely due to a variation in the normal lymphatic drainage, as shown in the rat where there may be direct communication between the testicular lymphatics and the thoracic duct. In addition, isolated metastases to the external iliac, inguinal and femoral nodes may occur as a result of surgical distortion or tumor involvement of the epididymis.

SECTION II: MODALITIES OF IMAGING FOR DIAGNOSIS AND STAGING

A. Ultrasonography

Ultrasound is a noninvasive, nonionizing modality which has gained wide acceptance for evaluation of the testes and other scrotal pathology. It is performed rapidly and without discomfort to the patient.

Ultrasound of the testicle is usually done in a patient presenting with an enlarged scrotum to differentiate between intratesticular and extratesticular masses (Figure

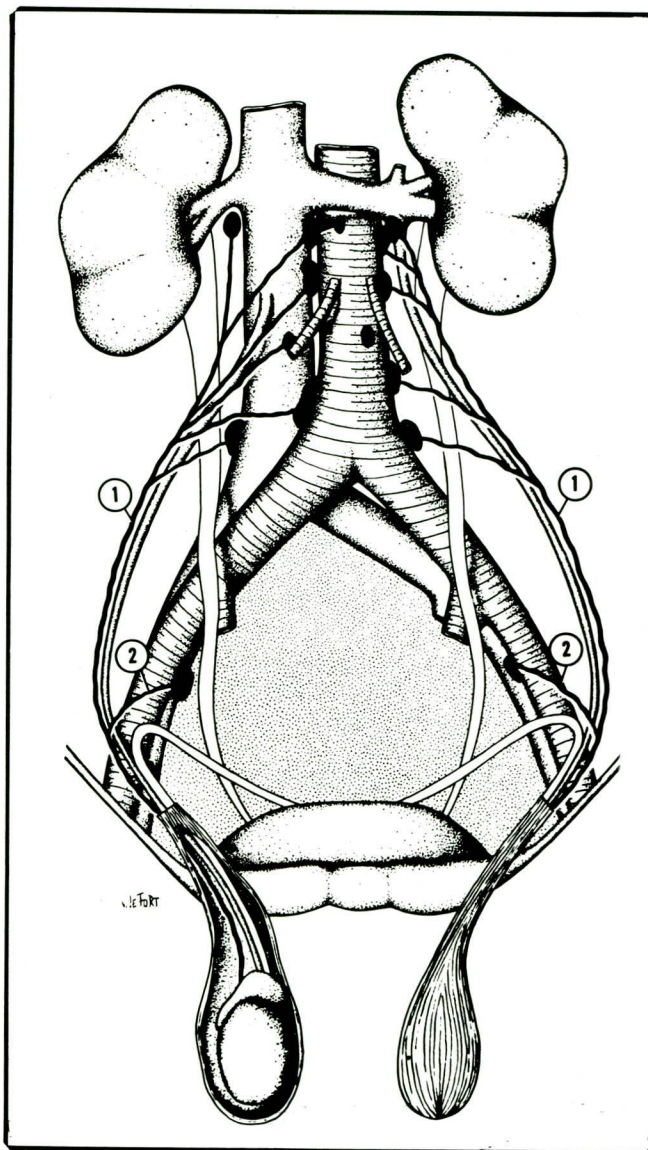


Figure 4 — Anatomy of lymphatic drainage of the testes.

1. The major draining trunks empty into the lumbar lymph nodes via sentinel nodes from the level of the renal hilum to the bifurcation of the aorta.
2. The external iliac nodes may occasionally drain the testes.

5). It is also useful in suspected testicular neoplasms, or in search of primary neoplasms which may be occult in patients presenting with metastatic disease. In addition, an undescended testicle alone or complicated by tumor may also be demonstrated by ultrasound^{6,9,10}. Finally after orchiectomy, with or without insertion of a prosthesis, the sac may be scanned in search of residual or recurrent tumors.

Technique. After a brief clinical history is obtained, the patient is placed in the supine position and with gloved hands, careful palpation of the scrotum and its contents is performed. A folded towel is placed between the thighs to keep the scrotum elevated. A second towel is spread between the scrotum and the

groin. The penis is folded upward and covered by another towel. Scanning may be performed with the scrotal contents either lying on the towel or cradled within the gloved hand of the operator. In any event, care must be taken to place the epididymis posteriorly. It would be preferable to have another person to assist marking the images with appropriate numbers and planes of scanning. The room temperature should be comfortably warm to prevent contraction of the scrotum during scanning.

At UT M.D. Anderson Hospital, high resolution 7.5 and 10-MHz small parts transducers are utilized. Scanning is begun using 7.5 MHz transducer in the transverse plane (preferably including both testicles in the field) and scans are numbered from the level of the head of the epididymis through the inferior pole. This will allow comparison of the echogenicity of the testicles. In larger testicles, each testicle may be scanned separately. Sagittal slices may be obtained from midline towards

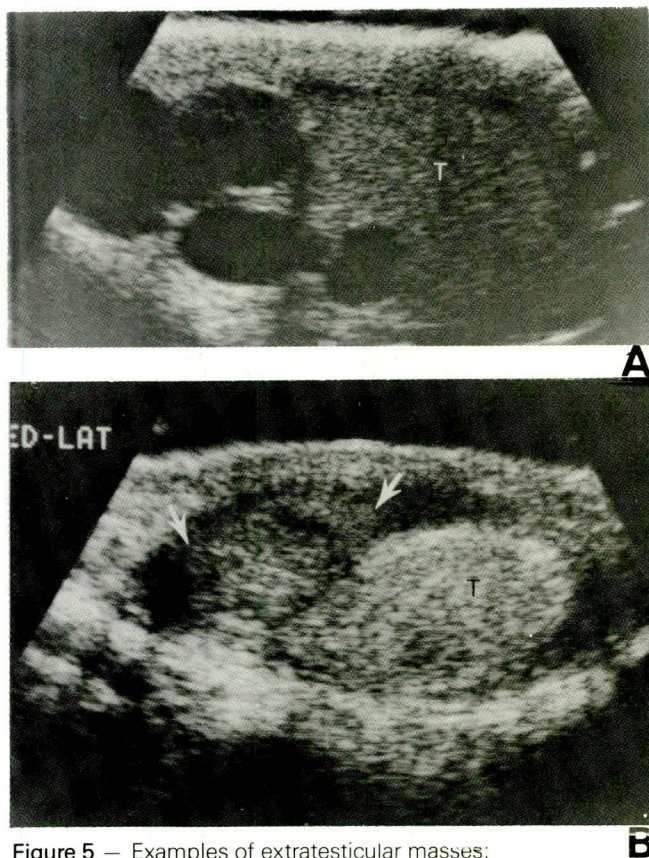


Figure 5 — Examples of extratesticular masses:

A. Spermatoceles: 50-year-old man with an enlarged scrotum. Sagittal sonogram shows numerous fluid filled interconnected spaces along the course of the epididymis displacing the testicle (T) caudally.

B. Epididymitis: 45-year-old male with recent onset of painless swelling of the right testicle. Sagittal sonogram shows an enlarged head of the epididymis (arrows) compressing the testicle (T). The possibility of an adenomatoid tumor prompted orchiectomy which showed acute purulent and chronic epididymitis as well as orchitis.

the lateral aspect and numbered as such. Finally, both testicles and the scrotum are carefully surveyed with a 10 MHz transducer and appropriate images and measurements of the lesion(s) are obtained.

Testicular tumors

Sonography is extremely accurate in differentiating intra- from extratesticular masses (Figure 5). This is of paramount importance as the majority of the intratesticular masses are malignant while almost all of the extratesticular masses are either inflammatory lesions or benign neoplasms⁵. Intratesticular masses arise either from the germ cells or the stroma. Other tumors include leukemia-lymphoma, and metastatic disease. Extratesticular masses include hydrocele, hematoma, spermatocele, abscess (Figure 5), and adenomatoid tumor^{5,11}. Sonographic features of the malignant intratesticular neoplasms consist of single or multiple masses, bright echogenic foci and diffuse abnormality of the echo texture^{5,12}. In one reported series of 21 patients, 72% of confirmed testicular neoplasms showed a mass on ultrasound, 66% had bright echogenic foci and 31% showed diffuse abnormality of the texture of the testicle, all these being ultrasonographic features of testicular neoplasm¹². It should be noted however, that focal intratesticular masses are non-specific and while usually neoplastic may also be representative of other pathologic processes such as abscess, infarction or hemorrhage⁶. Thickening of the scrotum and the epididymis has been described as a differentiating sign for inflammatory lesions¹³, however, certain neoplasms such as embryonal carcinoma frequently infiltrate the tunica and epididymis and therefore may mimic inflammatory lesions^{6,11}. Hyperechoic foci in a suspected neoplasm may represent "burnt-out" germ cell tumor or calcification within a teratoma. "Burnt-out" tumors are important ultrasonic findings in patients presenting with metastatic germ cell tumors and normal testicles on palpation^{5,12,14}. Sonographically, these foci are seen at the periphery of the mass or in an area of diffusely altered texture. They measure 2 to 5mm in size. They may or may not show acoustic shadowing (Figure 11). These testicles are usually atrophic as compared to the contralateral testicle and the echogenic foci represent a regressed germ cell tumor^{5,12,14}. Diffuse changes in the echo texture may be seen in the lymphoma-leukemia group^{6,15,16}, seminoma and mixed germ cell tumors^{12,17}.

While ultrasound findings are not specific, the incidence of a false-negative examination in tumors is very low. In another series, accuracy in detection of a neoplasm was found to be 80% to 90%⁶. This is of extreme importance in cases of metastatic germ cell tumors where no palpable mass is found in the testicle (occult testicular primary)^{6,17}.

Sonographic findings in specific tumors

Ninety-five percent of the testicular tumors are of germ cell origin which are highly aggressive tumors and 5% are nongerminal tumors, usually benign in nature. Of germ cell tumors, 60% are of pure cell type and 40% are mixed¹¹. Eight percent of the patients will be expected to develop a contralateral testicular tumor either of the same or different cell type (Figure 6)¹¹.

Seminoma

Seminomas are the most common cell type and account for 40% of the germ cell tumors. These tumors are never seen in infants and the peak age is in the fourth decade. Seminomas are less aggressive, highly radiosensitive and the cure rate for stage I disease approaches 95% to 100%^{3,11}. Twenty-five percent of the seminomas will present with metastatic disease. These tumors are almost always confined to the tunica albuginea and represent the most common germ cell tumor arising in the undescended testicle (Figure 23)^{5,6,11}. On sonography, seminomas usually present with solitary or multifocal hypoechoic^{5,6,18} lesions (Figure 6). Occasionally, they produce diffuse hypoechogenicity^{12,17}.

Embryonal carcinoma

Embryonal carcinoma is the most undifferentiated and the stem for all nonseminomatous germ cell tumors. These account for 20% of the germ cell tumors and occur in a younger age group than seminoma, usually between 15 and 30 years of age. They frequently invade the tunica and the epididymis and may contain necrosis and hemorrhage^{6,11}. On sonography, they manifest as well defined lesions which are less homogeneous than seminomas and contain both cystic and echogenic areas⁵.

Teratoma

Teratomas represent 5% to 10% of the primary germ cell tumors of the testicle and while they are frequently thought to be benign tumors, approximately one-third metastasize within five years⁵. The mature (differentiated) forms in children behave as benign tumors and almost all have a good prognosis. In the adults, it is difficult to be certain and apparently differentiated mature teratomas may harbor foci of malignant cells; therefore, it is believed that all teratomas in the adults should be considered malignant¹¹. The sonographic appearance of the teratomas depends on the complex nature of these lesions; they may range from sonolucent to highly echogenic lesions (Figure 7). The cystic ones will present as sonolucent defects. Calcium and osseous components will create highly echogenic lesions with acoustic shadowing⁵. A primary teratoma in the testicle may metastasize to the retroperitoneal nodes as a

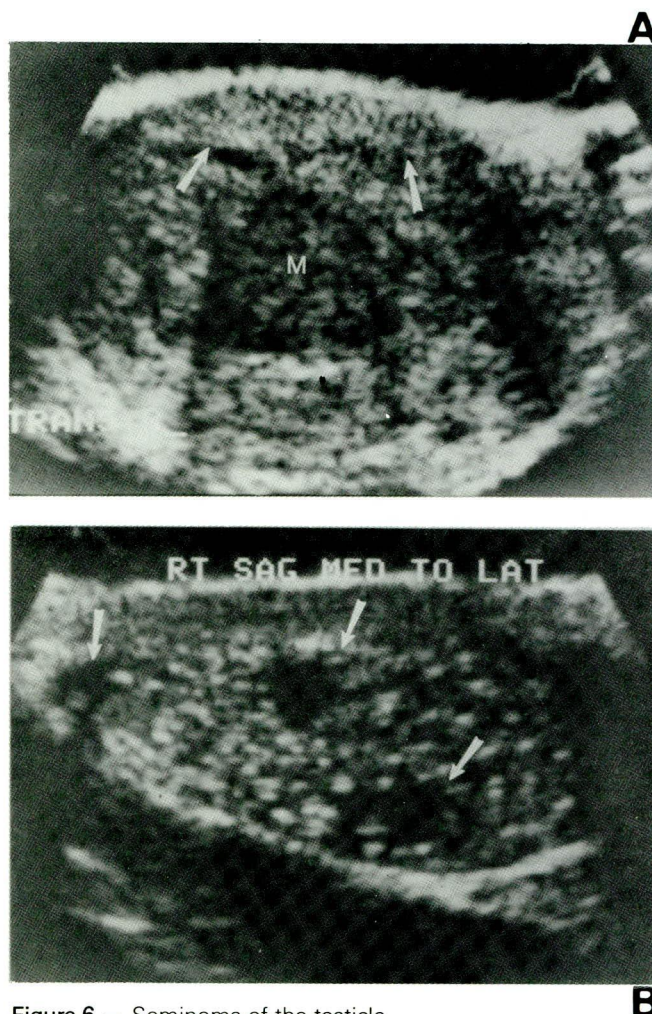


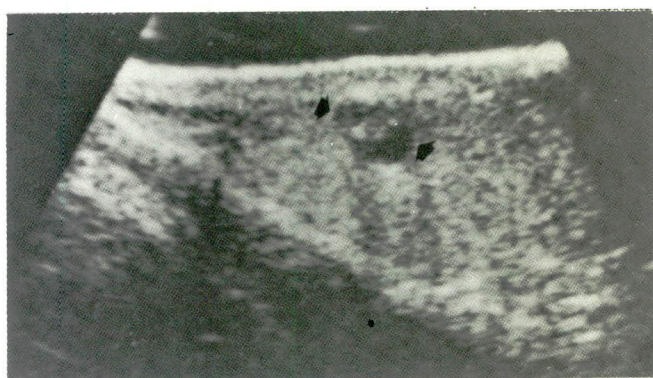
Figure 6 — Seminoma of the testicle.

A. Unifocal pattern: 26-year-old male with right testicular mass. Sagittal sonogram showing a large centrally hypoechoic mass (M). Notice a rim of normal testicular tissue (arrows). On pathological examination, the testicle measured 5x4.5x3.5cm containing a well-circumscribed mass measuring 4.3x4x2.5cm with a rim of uninvolved tissue and extensive necrosis in the tumor corresponding to the hypoechoic area on sonogram. B. Multifocal pattern: 24-year-old male with a nodule on the right testicle. The left testicle had been removed 18 months previously for a mixed germ cell tumor (Embryonal carcinoma, teratoma and seminoma.) Sagittal sonogram shows three hypoechoic lesions (arrows). Only the upper pole lesion was palpable clinically. Detailed pathological examination revealed four nodules in keeping with the multiple lesions seen on ultrasound.

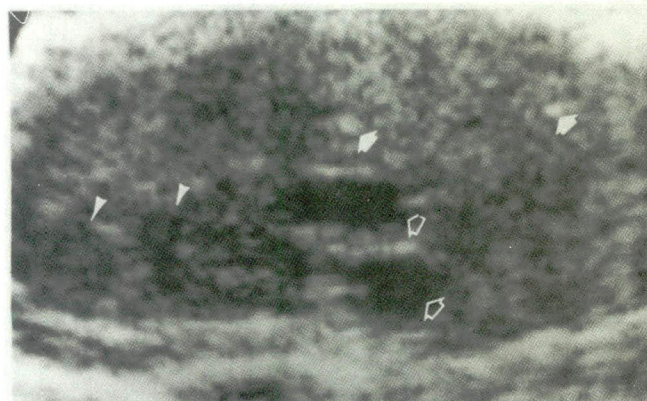
mixed germ cell tumor (Figure 7) and conversely a mixed germ cell tumor of the testicle may metastasize as a mature teratoma¹¹. These latter metastatic lesions may enlarge in size without containing malignant cells, so called growing teratoma syndrome (Figure 19)¹⁹.

Choriocarcinoma

Choriocarcinoma is the least common of the germ cell tumors accounting for 1-3% of these tumors. They are usually small, very aggressive tumors containing hemorrhagic and necrotic foci⁵⁻¹¹. As expected, human



A



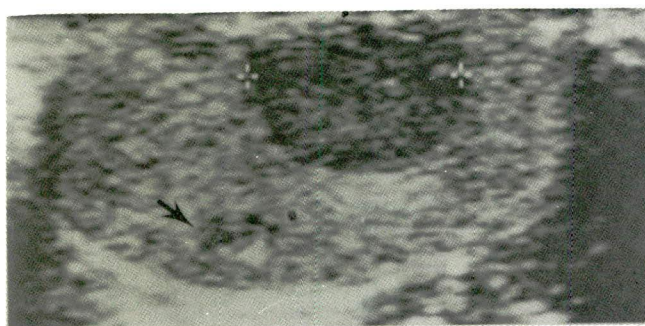
B

Figure 7 — Teratoma of the testicle.

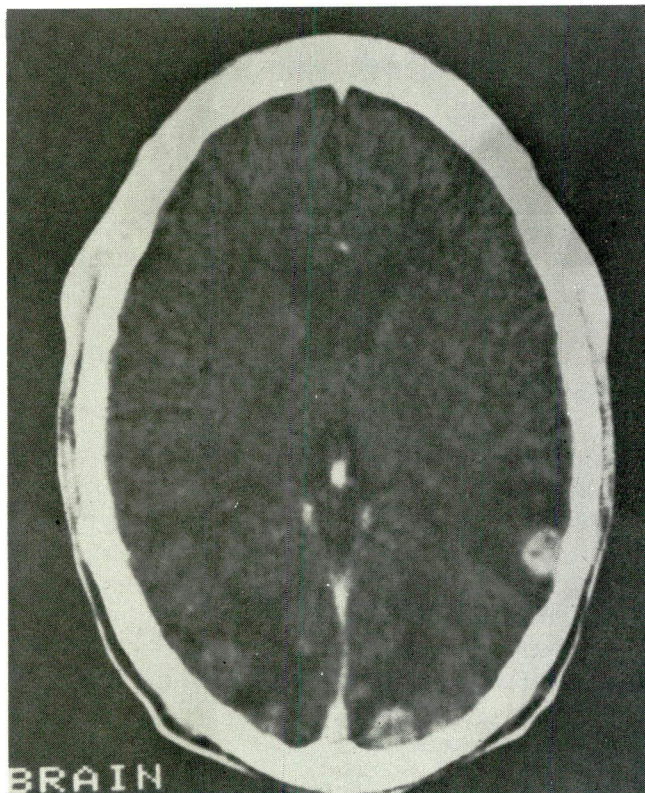
A. Cystic pattern with solid component: 37-year-old male with supraclavicular node positive for metastatic poorly differentiated carcinoma of germ cell origin. Sagittal sonogram shows small cystic lesion (arrows) with mural nodule.

Pathological examination of the testicle and retrocrural nodes revealed mature teratoma whereas the retroperitoneal nodes showed embryonal carcinoma.

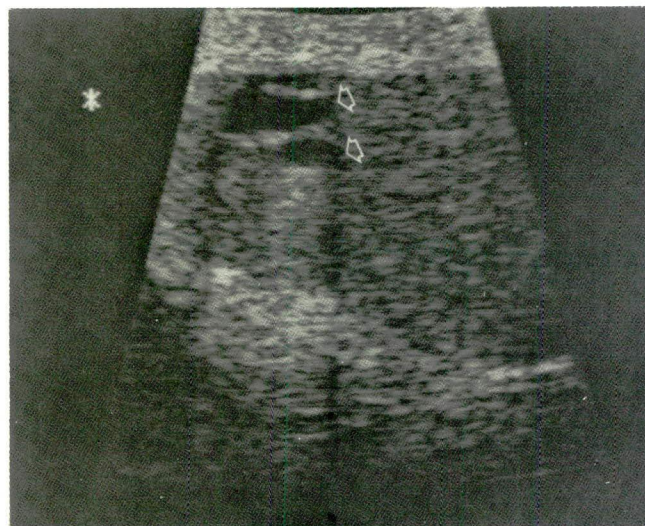
B. Diffuse and focal pattern: 22-year-old male with an enlarged testicle and pulmonary parenchymal and mediastinal metastases. Sagittal sonogram shows a diffusely abnormal echo texture with cystic (open arrows), hyperechoic (closed arrows) and hypoechoic (arrowheads) foci. Pathologically the testicle was found infiltrated by mature teratoma with partially cystic and necrotic areas.



A



B



C

Figure 8 — Choriocarcinoma probably arising from an undescended testicle metastatic to lung and brain.

32-year-old male with disseminated choriocarcinoma diagnosed by lung biopsy. He had a history of undescended testicle, surgically corrected during infancy. Two hard nodules were palpable in the right testicle.

A. Sagittal sonogram prior to chemotherapy showing a discrete hypoechoic nodule (cursors) and a possible smaller one (arrow).

B. Postcontrast brain CT scan showing multiple enhancing metastases.

C. Postchemotherapy sonogram showing two cystic areas (arrows). Subsequent orchiectomy showed three small nodules. Pathologic diagnosis was cystic mature teratomas with 90% fibrosis. No choriocarcinoma was detected.

chorionic gonadotropin (HCG) is demonstrated in the cytoplasm of the syncytiotrophoblastic cells and as a result choriocarcinomas exclusively produce HCG. Choriocarcinomas cause early metastatic disease (Figure 8) and may be a component of other germ cell tumors. These tumors may metastasize as choriocarcinoma without choriocarcinoma being found in the testicular primary (Figure 8)¹¹. On ultrasound, they present with mixed echogenic pattern due to necrosis, hemorrhage, and calcification.

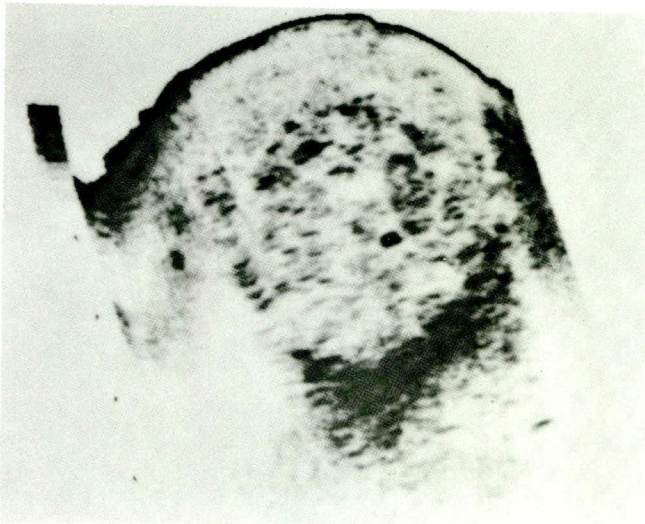
Endodermal sinus tumor

Endodermal sinus tumors, also known as infantile embryonal carcinoma or yolk sac tumors, are the most

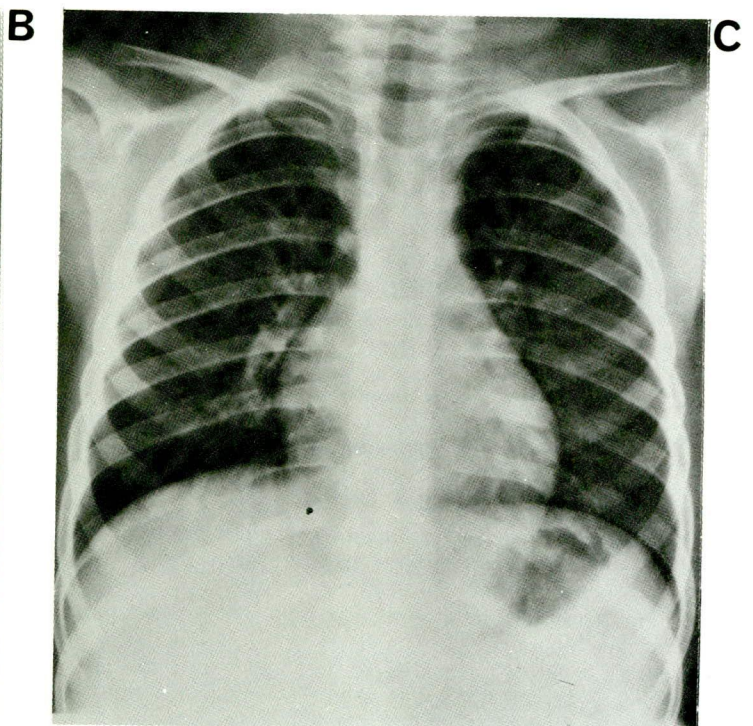
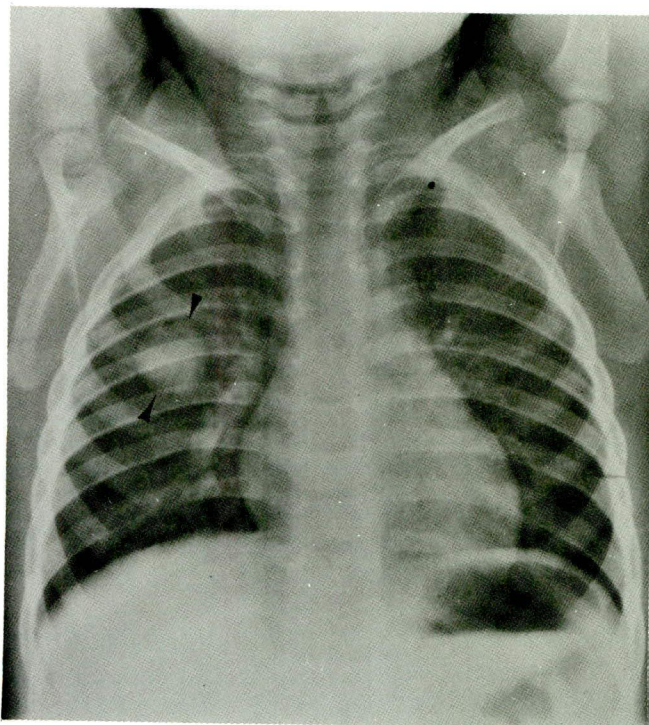
common testicular tumors in infants and children¹¹. Pure endodermal sinus tumor is rare in adults²⁰ and is usually seen in association with embryonal carcinoma. These tumors produce exclusively alpha-fetoprotein (AFP). On ultrasound, these may present as hypoechoic or echogenic masses (Figure 9).

Mixed tumors

Mixed tumors constitute the remaining 40% of the germ cell tumors. The most common histologic type (25%) is the combination of teratoma and embryonal carcinoma (so called teratocarcinoma) and represents the second most common type of all germ cell tumors, second only to seminoma. These tumors contain cysts,



A Figure 9 — Metastatic endodermal sinus tumor of the testicle. Two-year-old boy with testicular mass, pulmonary and retroperitoneal metastases.
 A. Sagittal sonogram shows an enlarged echogenic testicle.
 B. Prechemotherapy chest radiograph shows a metastatic nodule (arrowheads).
 C. Postchemotherapy chest radiography three months later shows resolution of the nodule.



hemorrhage, and necrosis. They frequently invade the tunica and epididymis and consequently lymphatic and hematogeneous metastatic disease occurs early^{5,6,11} On sonography, these tumors may appear as solitary or multiple hypoechoic nodules, complex cystic-solid lesions or diffuse change in texture (Figure 10).

Extragonadal germ cell tumors

Extragonadal germ cell tumors may occur in the retroperitoneum, mediastinum, and pineal gland. Before a patient is diagnosed as having extragonadal germ cell tumor, a thorough search of the testicle by ultrasound should be performed to exclude a gonadal primary. Sonography of testicles in some patients with presumed extragonadal germ cell tumors may show bright echogenic foci representing so called "burned-out" germ cell tumors (Figure 11)^{5,12,14,17}. Histologically these foci may contain hematoxyphilic bodies, immature bone, hyaline cartilage, calcification or tubular atrophy. These testicles are usually smaller than the contralateral testicle. These foci may or may not have distal acoustical shadowing. In one series, these foci were seen in 87% of the patients who had regressed germ cell tumor¹².

Non-germ cell tumors

Non-germ cell tumors account for 5% of the testicular tumors and they are usually of Sertoli-Leydig variety. These are usually benign in nature and may produce endocrinology manifestations. On sonography, they are usually solid hypoechoic masses containing cystic foci⁵.

Lymphoma and leukemia

Lymphoma is not a primary tumor of the testicle and constitutes about 5% of testicular neoplasms. It is the most common testicular tumor in elderly men. Disseminated disease usually follows testicular involvement. The histologic pattern is diffuse in almost all of the cases. The sonographic appearance is that of diffusely enlarged hypoechoic testicle, although occasionally multifocal involvement may be seen (Figure 12)⁵⁻¹⁸.

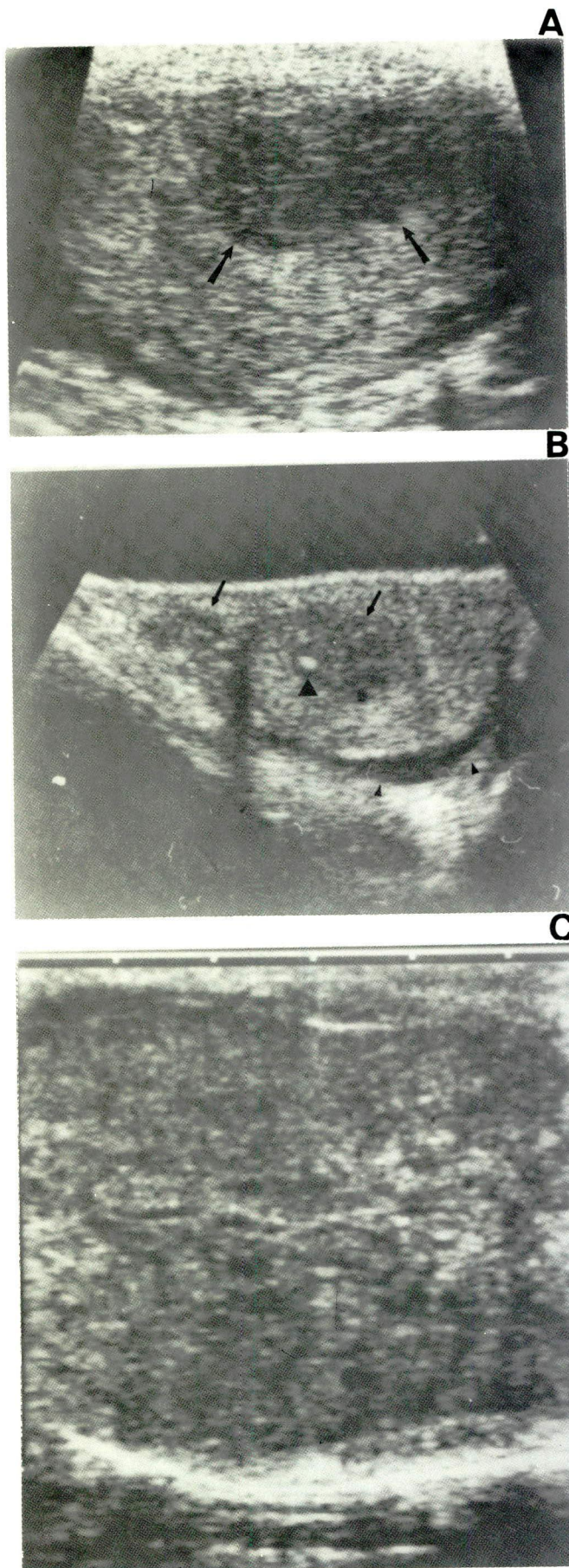


Figure 10 — Mixed germ cell tumors of the testicle.

A. Unifocal hypoechoic pattern (arrows). (Dx: Seminoma + Embryonal carcinoma.)

B. Multifocal hypoechoic pattern (arrows) and bright hyperechoic focus (large arrowhead). Notice small hydrocele (small arrowheads).

(Dx: Embryonal carcinoma, endodermal sinus (yolk sac) tumor and mature teratoma.)

C. Diffuse pattern. Notice diffuse distortion of normal texture. (Dx: Embryonal carcinoma, endodermal sinus tumor, mature and immature teratoma, choriocarcinoma and seminoma.)

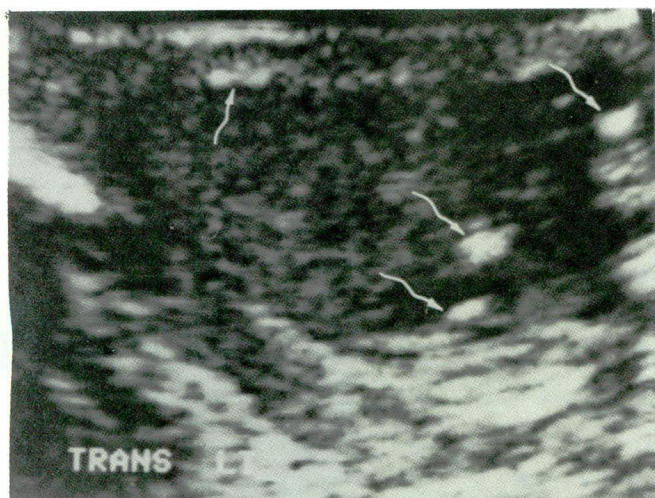


Figure 11 — “Burnt out” germ cell tumor of the testicle. A 24-year-old man with history of metastatic germ cell tumor in retroperitoneal nodes (EST and choriocarcinoma) treated two years ago with chemotherapy. Transverse sonogram of the testicle showing abnormal texture and multiple bright hyperechoic foci (arrows). Histology showed a small cyst, an island of hyaline cartilage and extensive fibrosis consistent with “burnt out” or differentiated tumor (mature teratoma).

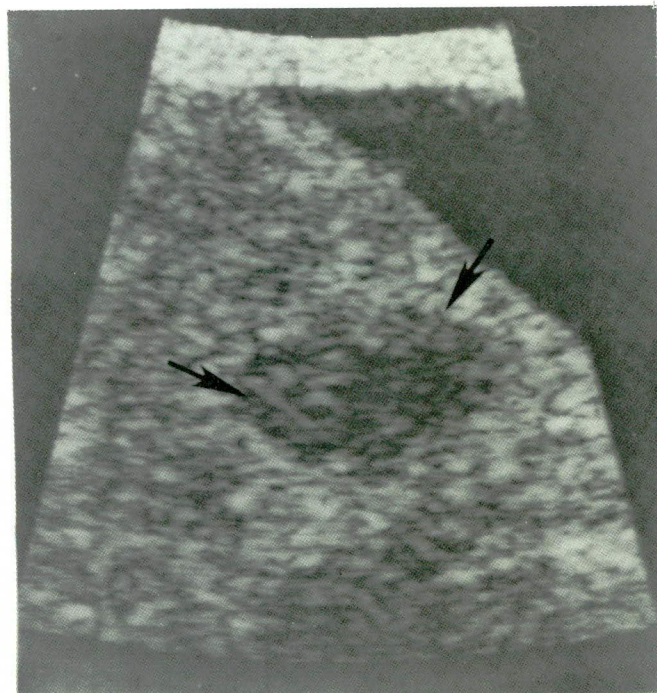


Figure 12 — Lymphoma of the testicle. An 18-year-old male with lymphoblastic lymphoma presenting with bilaterally enlarged testicles and retroperitoneal adenopathy. Transverse sonogram shows one of the hypoechoic nodules (arrows).

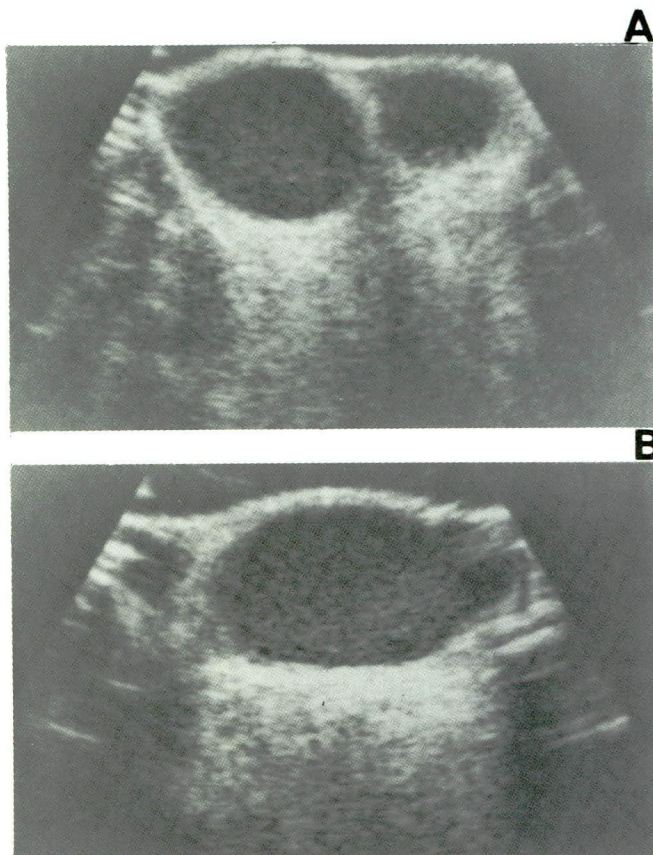


Figure 13 — Testicular relapse in leukemia. A seven-year-old with history of acute lymphoblastic leukemia in remission, presenting with bilaterally enlarged testicles. Transverse (A) and sagittal (B) sonograms show asymmetrically enlarged and diffusely hypoechoic testicles.

Testicular involvement in acute lymphoblastic leukemia during the initial presentation is occasionally seen, however, most cases occur within one year of discontinuation of maintenance chemotherapy. The incidence of leukemic relapse in the testicle has been reported to be as high as 13% and probably represents an early manifestation of more occult systemic disease^{15,16}.

Sonography at the completion of maintenance chemotherapy and thereafter may demonstrate early relapse and obviate the need for routine wedge biopsy. Sonographically leukemia manifests with enlarged diffusely hypoechoic testicles (Figure 13), although focal hypoechoic nodules are not uncommon. These focal areas of involvement may escape detection on clinical examination.

Metastases

Metastatic tumors to the testicle are more common than germ cell tumors in men over 50 and are usually from genitourinary primaries (prostate, kidney). On sonography these may appear as either hypoechoic or hyperechoic defects⁵.

Extratesticular tumors

Among the extratesticular tumors, adenomatoid tumor is the most common and arises from the epididymis^{5,11}. These are usually small benign tumors and are seen in the periphery of the testicle, as a solid mass usually more echogenic than the testicle⁵.

Ultrasound in the evaluation of nodal metastasis

Ultrasound may be utilized in search of nodal metastasis in the abdomen and pelvis. However, the retroperitoneum is frequently obscured by gas, especially in the lower abdomen and pelvis.

Ultrasound of the scrotum following orchiectomy

Following orchiectomy, a baseline sonogram should be obtained preferably 4-6 weeks postoperatively. This will allow time to record the status of the contralateral testicle and presence of residual or recurrent tumor in the hemiscrotum with or without prosthesis (Figure 14).

Computed tomography

While ultrasound can be utilized in the evaluation of the retroperitoneal spread of testicular tumors, the lower paraaortic nodes are frequently obscured by the interfering bowel gas and obesity of the patient. CT scan is extremely helpful in staging because it more accurately

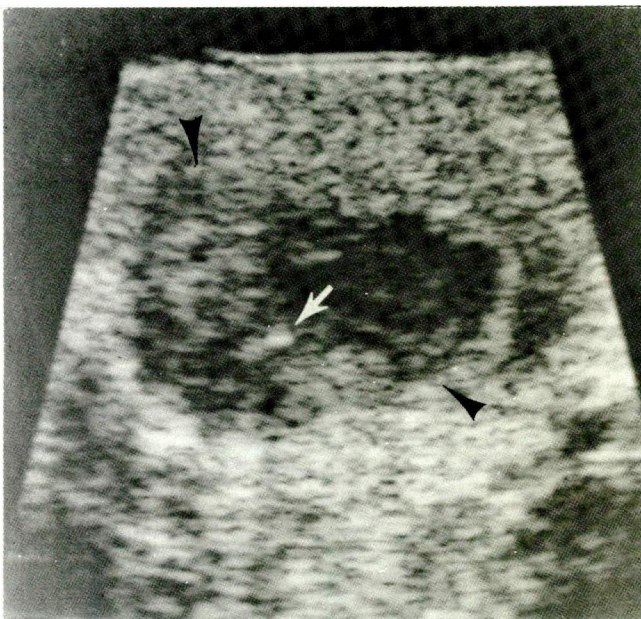


Figure 14 — Tumor recurrence in the postorchietomy space. A 27-year-old male status one month postorchietomy for mixed germ cell tumor invading the capsule and epididymis. There were also retroperitoneal metastases. A 1.5cm nodule was palpable in the right sac. Saggital sonogram shows a 1.5cm hypoechoic mass (arrowheads). Notice small calcification (arrow). Following chemotherapy, both the nodule and retroperitoneal nodes regressed.

Table 2 — UT MDAH classification of neoplasms of the testis and related structures

I. Neoplasms of testis proper	
A. Germinal tumors	
1.	Seminoma, pure
a.	Classic type
b.	Anaplastic type
c.	Spermatocytic type
2.	Embryonal carcinoma, pure, or with seminoma
a.	Juvenile variant
3.	Teratoma, pure, or with seminoma
a.	Mature
b.	Immature
4.	Teratoma with embryonal carcinoma or choriocarcinoma or both, with or without seminoma
5.	Choriocarcinoma, pure or with embryonal carcinoma or seminoma or both
B. Gonadal stromal tumors	
1.	Interstitial cell tumor
2.	Tumor of specialized gonadal stroma
a.	Androblastoma
b.	Sertoli cell tumor
c.	Granulosa cell tumor
C. Secondary neoplasms	
1.	Reticuloendothelial neoplasms
a.	Malignant lymphoma, various types
2.	Metastatic neoplasms
a.	Adenocarcinoma of prostate
b.	Malignant melanoma
c.	Bronchogenic carcinoma
d.	Other
II. Neoplasms of related structures	
A. Connective tissue neoplasms	
1.	Paratesticular rhabdomyosarcoma
2.	Nonspecific connective tissue neoplasms
3.	Granulosa cell tumor
B. Other neoplasms	
1.	Adenomatoid tumor of epididymus
2.	Papillary cystadenoma of epididymus
3.	Mesothelioma of tunica vaginalis testis

ly determines the extent of tumor preoperatively in most instances. In seminomas, it helps in radiation therapy treatment planning. In non-seminomatous tumors, the therapeutic modality chosen, namely surgery versus chemotherapy, may be guided by the CT findings^{4,21}.

Reported accuracy of CT in the detection of retroperitoneal nodal metastasis is approximately 85% and it may detect early metastatic disease to the renal hilar nodes which are not opacified by bipedal lymphangiography (LAG)^{4,7,8}. CT will help to depict the exact extent of the tumor, particularly in the upper periaortic regions. In addition, CT scan will demonstrate extranodal metastatic disease (liver, lung)^{3,21}. Though larger lateral masses (> 1.5cm) can be better defined by CT, when the disease is small and the changes are subtle, the nodes are better defined by LAG (Table 3). However, CT and LAG are really complementary studies (see below)⁷. In addition, CT can be used for monitoring the

Table 3 — CT versus lymphangiography

Usage/Indications*	Computed tomography	Lymphangiography
To reveal flow dynamics		+
To detect small nodal lesion		+
To detect large nodal lesions	+	
To determine the extent of nodal lesions	+	
To reveal extranodal involvement	+	
To delineate nodes beyond LAG demonstration	+	
To detect internal architecture		+
*CT and LAG are complementaries		

response to treatment in patients with elevated levels of tumor markers⁴.

Technique:

CT scans of the chest are obtained at 10mm contiguous slices from the apices through the lung bases. Intravenous contrast is routinely utilized. CT scans of the abdomen are taken with 15mm slices at 10mm intervals and from the pelvis 15mm slice intervals. Oral, intravenous and rectal contrast material are routinely used. In the search for an undescended testis, smaller (10mm) slice intervals are selected. Further evaluation by scans at closer intervals (3mm to 5mm) is determined after review of the initial surgery.

Computed tomography in imaging of metastatic testicular tumors

CT findings of metastatic masses from testicular tumors may be divided into three different groups: cystic, solid, and mixed²².

The cystic pattern is seen in pure very mature teratomas (Figures 15, 25). The solid pattern is usually seen in pure seminoma (Figure 16) or pure choriocarcinoma. The semicystic (mixed) pattern is due to teratomatous components either metastasis from a pure primary immature teratoma or of primary mixed germ cell origin with teratomatous components (Figure 17). The degree of cystic change in a pure teratoma is directly proportional to the maturity of the teratoma, the more mature the teratoma the more cystic the appearance (Figure 25)²².

Low attenuation nodal metastases occurs in 43-46% of testicular cancer. A low attenuation mediastinal or retroperitoneal mass of unknown etiology in a young male should raise suspicion of a metastatic testicular neoplasm^{23,24}.

Persistent masses detected by CT are common after chemotherapy of seminomas and create a diagnostic

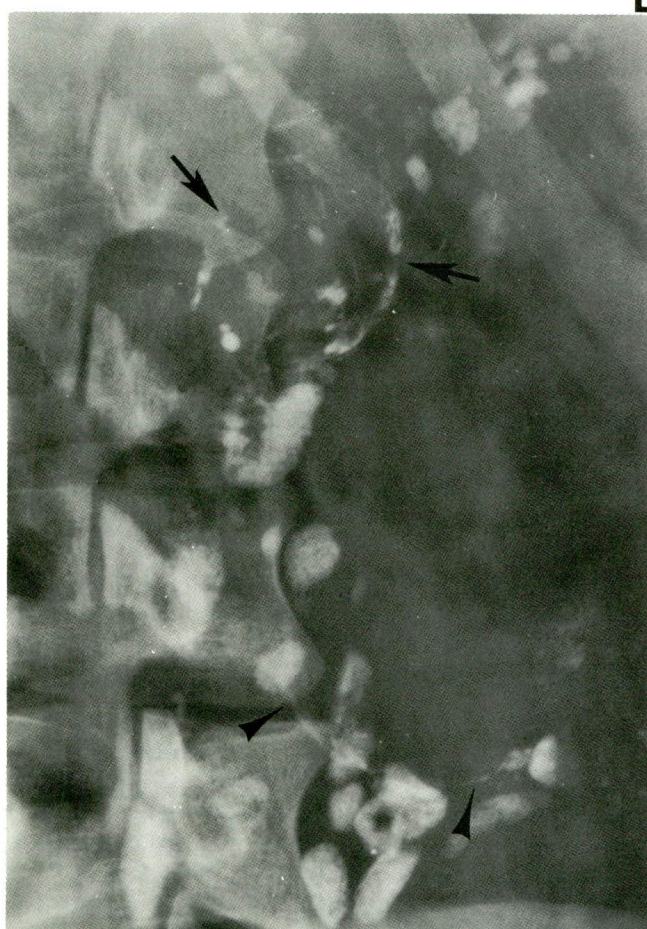
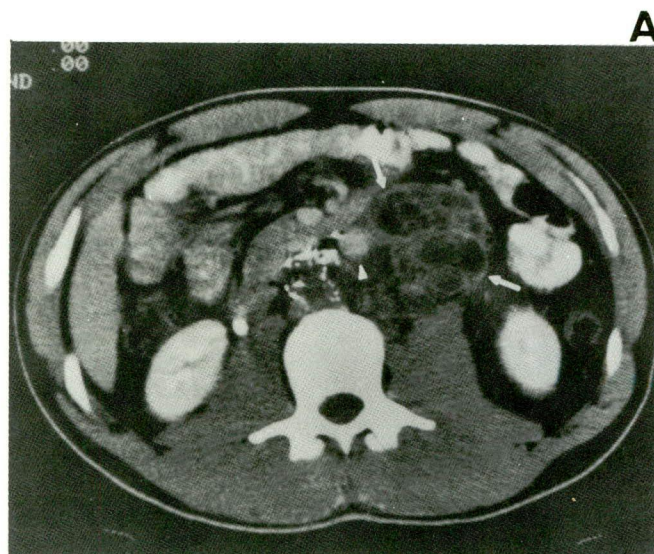


Figure 15 — Retroperitoneal metastasis from mixed germ cell tumor (Embryonal carcinoma, endodermal sinus tumor and mature teratoma) of the testicle cystic pattern:
 A. CT scan shows septated cystic mass (white arrows) displacing the aorta (white arrowhead). The low density of the mass was consistent with its teratomatous component.
 B. LAG shows nodal metastasis, mostly non-opacified in left upper paraaortic area (black arrows) and a huge nodal mass inferiorly (black arrowheads) almost completely filled by tumor.

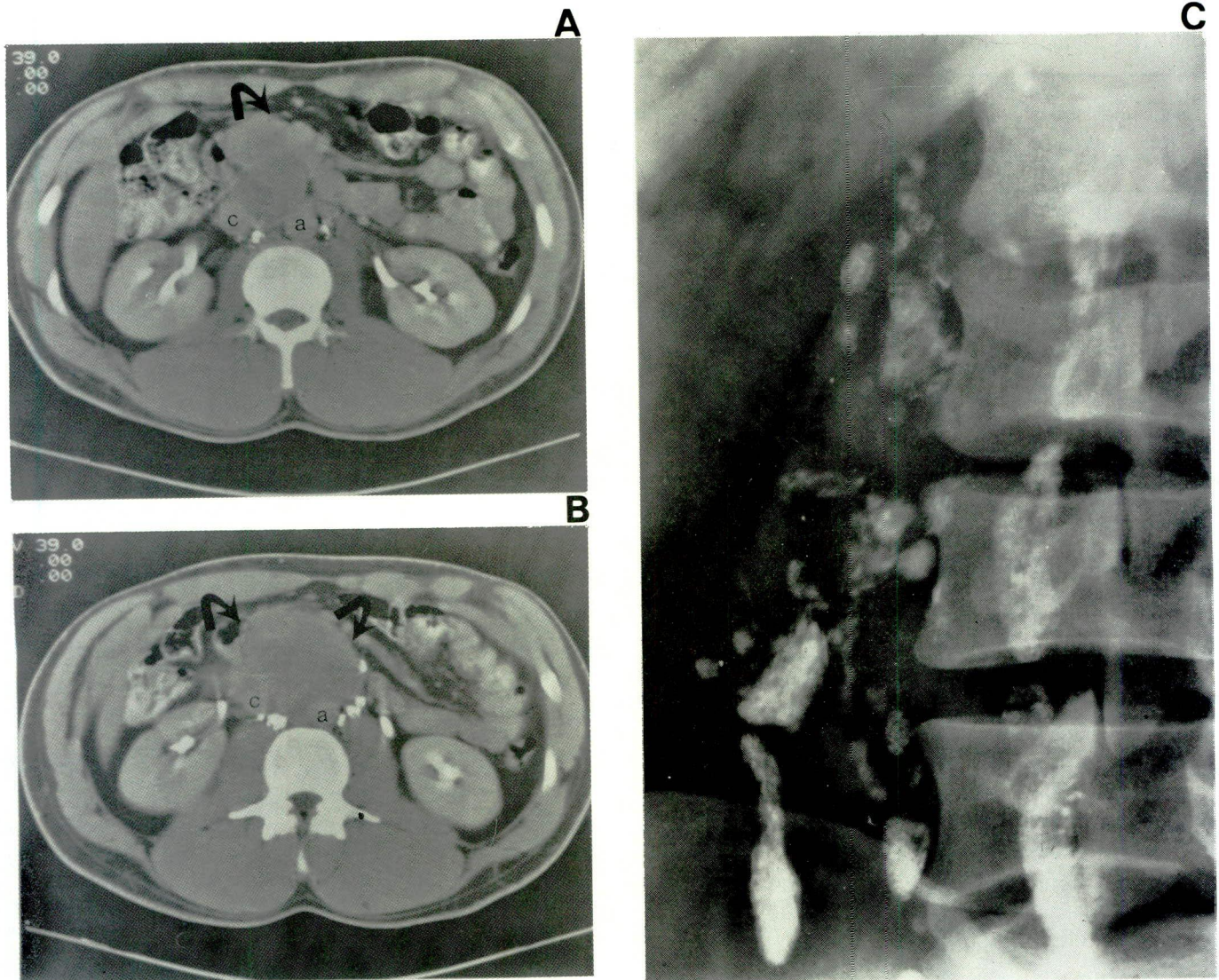


Figure 16 — Mixed germ cell tumor (seminoma embryonal carcinoma) of the testicle metastatic to retroperitoneal nodes, solid pattern.

A. and B. CT shows a large soft tissue mass anterior to the aorta (a) and inferior vena cava (c).
C. LAG shows multiple abnormal nodes, carcinoma pattern (see text).

dilemma^{25,26}, frequently requiring biopsy under CT guidance. Unlike their nonseminomatous counterpart they most often represent fibrosis²⁷. Residual low attenuation masses represent necrosis with lipid-laden macrophages and cholesterol clefts (Figure 18)²⁴.

In 1.9% of patients with metastatic mixed germ cell tumors treated with chemotherapy, recurrence of a solitary enlarging mass in the chest or abdomen has been described as the "growing teratoma" syndrome¹⁹. On surgical resection, these prove to be mature teratomas with no malignant features on histology (Figure 19). In two out of six patients reported from this institution, the growth was attributed to an expanding cystic nature of the mass; the remaining four had firm masses. Tumor biomarkers were normal in these cases and surgery was curative.

Aspiration needle biopsy of the retroperitoneal nodes may be performed under CT guidance; however, if the nodes contain lymphangiographic contrast the biopsy can be done under fluoroscopy. CT is also of value in diagnostic needle aspiration and drainage of lymphoceles that result from retroperitoneal node dissection.

C. Lymphangiography (LAG)

Lymphangiography in tumors of the testes:

Unlike the lumbar nodes, the sentinel nodes are usually not opacified by bipedal LAG. Thus, in the final analysis important nodes are filled by testicular LAG that are not opacified by the pedal route, necessitating

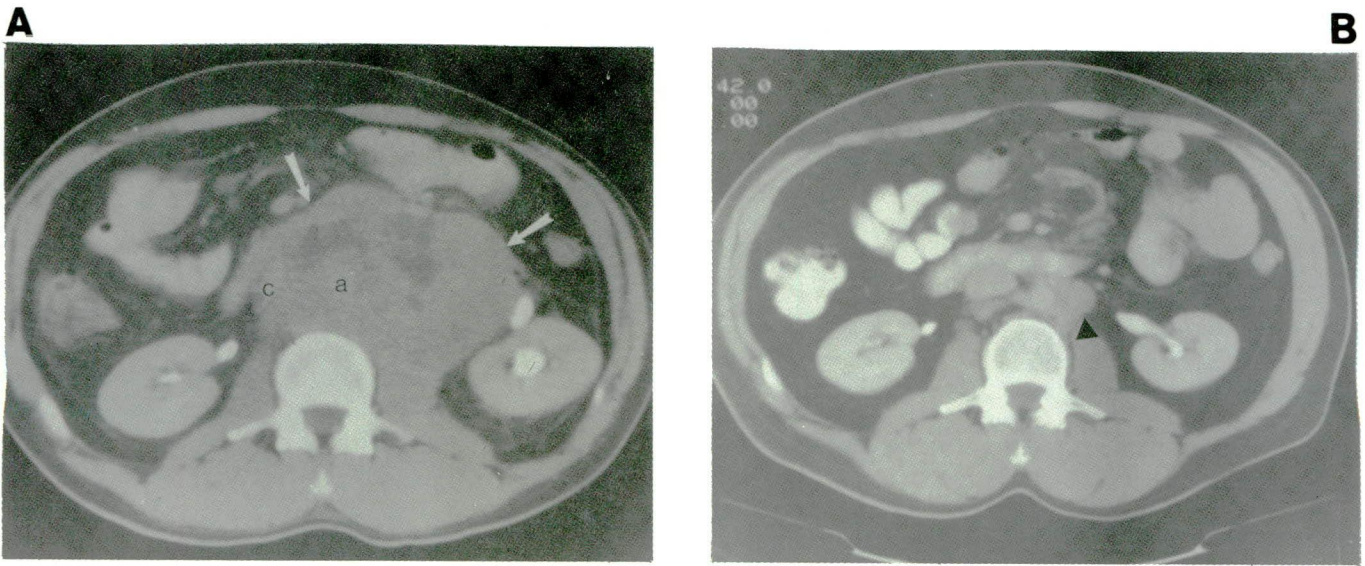


Figure 17 — Seminoma of the testicle metastatic to the retroperitoneal nodes, mixed pattern.
 A. CT scan one month postcommencement of chemotherapy shows huge mass (arrow) engulfing the cava (c) and aorta (a) with areas of low attenuation, presumably representing necrosis.
 B. CT scan three years posttreatment shows residual small left paraaortic node (arrowhead).

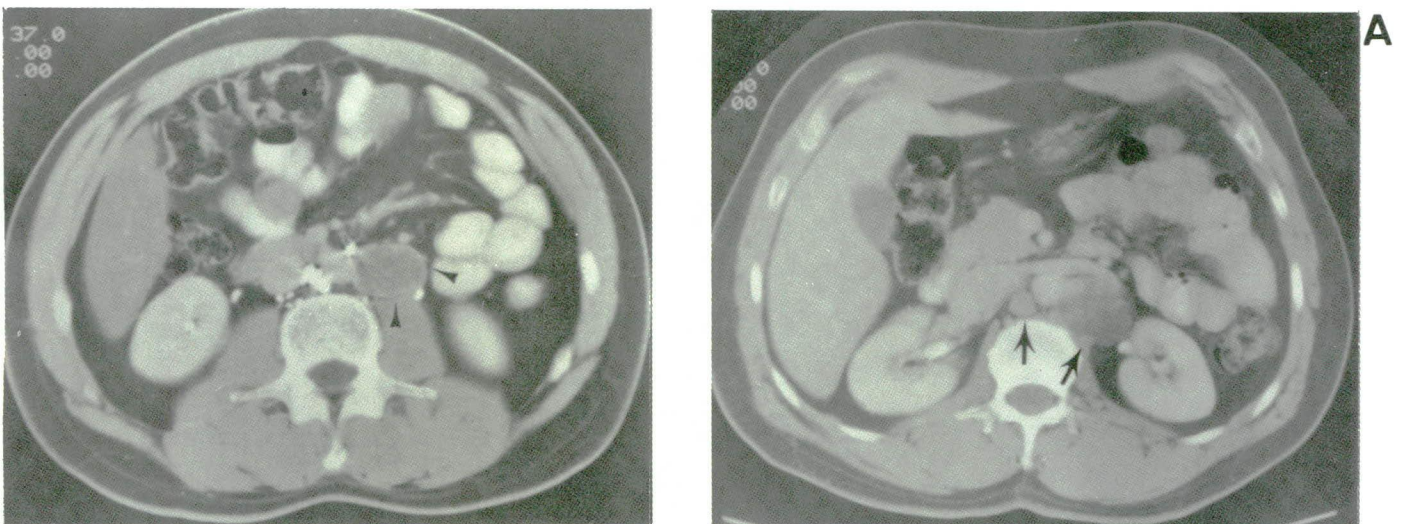
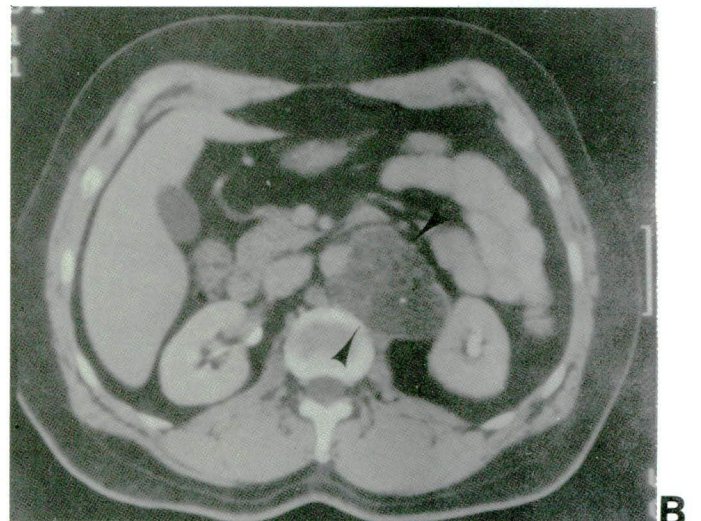


Figure 18 — Seminoma of the testicle with stable residual retroperitoneal mass.
 A 29-year-old male with history of metastatic seminoma treated with chemotherapy.
 CT scan shows a residual low density probably a necrotic mass in the left paraaortic area which has remained stable for at least 3 months.

Figure 19 — “Growing teratoma” syndrome.
 A 39-year-old male was treated for metastatic embryonal carcinoma of the left testicle. The patient was clinically free of disease and biomarkers were normal. Pulmonary metastases had disappeared.
 A. CT scan in March 1986, showing low density left paraaortic and interaortacaval nodes (arrows).
 B. CT scan in July 1986, shows increase in the size and further decrease in attenuation of the paraaortic mass (arrowheads).
 The mass was surgically resected and a mature teratoma was diagnosed. No further therapy was given.



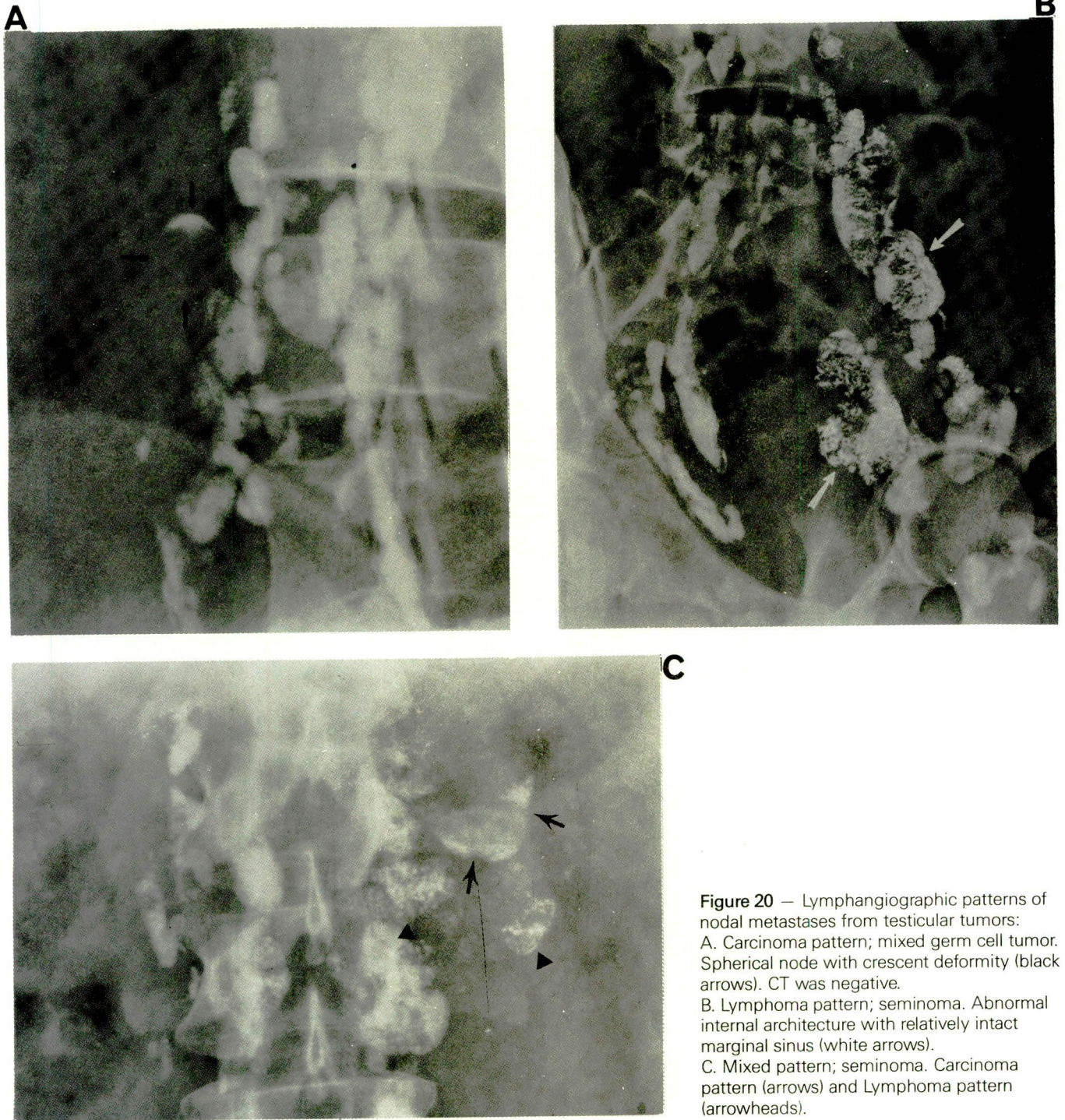


Figure 20 — Lymphangiographic patterns of nodal metastases from testicular tumors:
 A. Carcinoma pattern; mixed germ cell tumor. Spherical node with crescent deformity (black arrows). CT was negative.
 B. Lymphoma pattern; seminoma. Abnormal internal architecture with relatively intact marginal sinus (white arrows).
 C. Mixed pattern; seminoma. Carcinoma pattern (arrows) and Lymphoma pattern (arrowheads).

the combined approach for maximum information. However, in practice, this is seldom resorted to because of the risk of the operative procedure and the additional expense^{7,8}.

Nodal metastases from testicular malignant disease show several different architectural patterns. Involved nodes are more spherical than normal and may have a crescent deformity with the lymphatics that fail to penetrate the marginal defects (carcinoma pattern)

(Figures 16, 20). Occasionally, they may have an abnormal internal architecture with a relatively intact marginal sinus (lymphoma pattern) (Figure 20). The latter picture is more frequently seen in some seminomas, lymphomas, and rhabdomyosarcomas of the testes. At times, the metastatic nodes show both carcinoma and lymphoma patterns, a mixed variety (Figure 20)^{7,8}. At times, there may be immediate crossover metastasis from the right testicular lymphatics to the contralater-

al nodes (Figure 21). In our series of a total of 83 patients considered negative by lymphangiography, 70 were negative at surgical exploration. Of the 13 patients (11%) who exhibited false negative findings, four showed microscopic lesions 3mm or less in size, one had a lesion in the interaortico-caval area, and eight were found to have metastases in nodes lateral to those usually opacified by pedal LAG. These metastasis may have been diagnosed by the testicular route, ultrasound or CT. The overall accuracy by lymphangiography was 88.4%. Following lymphangiography, the patients can be monitored by conventional radiography of the abdomen in 75% of patients for one year and in 30% for two years (Figure 21).

Computed tomography versus lymphangiography in tumors of the testicle

The relative indications and usage of these two modalities of imaging are outlined in Table 3. At M.D. Anderson Hospital and Tumor Institute, in a comparative study of LAG and CT, CT scans were performed within a month following LAG in 103 patients with testicular tumors (82 with carcinoma and 21 with seminoma). Of

these 103 patients (Table 4), LAG was positive for nodal metastases in 53 patients and was negative in 50. CT detected metastasis in 50 patients and no metastases in 53 patients. Thirty-nine of 103 patients had pathological correlation by retroperitoneal lymph node dissection or percutaneous needle biopsy (34 with carcinoma and 5 with seminoma) (Table 5). LAG was proven to be positive in 29 patients with an overall accuracy of 92.3%. Twenty-six patients were positive on CT, with an overall accuracy of 84.6%. The five false negatives in the CT group were due to small lesions less than 1.5-2cm. Two false negatives in LAG (5.1%) resulted from a microscopic lesion in one case and a lesion in the pre-aortic and the interaortico-caval regions in another case. One false positive (2.5%) in the CT group was due to lymphoid hyperplasia and one false positive in the LAG group was caused by a benign lesion, sinus histiocytosis. In advanced testicular tumors, LAG often failed to reveal the upper limits of the lesion; however, CT is of definite value in demonstrating the extent of the nodal metastases and the involvement of the adjacent organs^{4,7,8,10}. Sometimes when the nodal lesion is high in the renal hilar region, it is often partial-

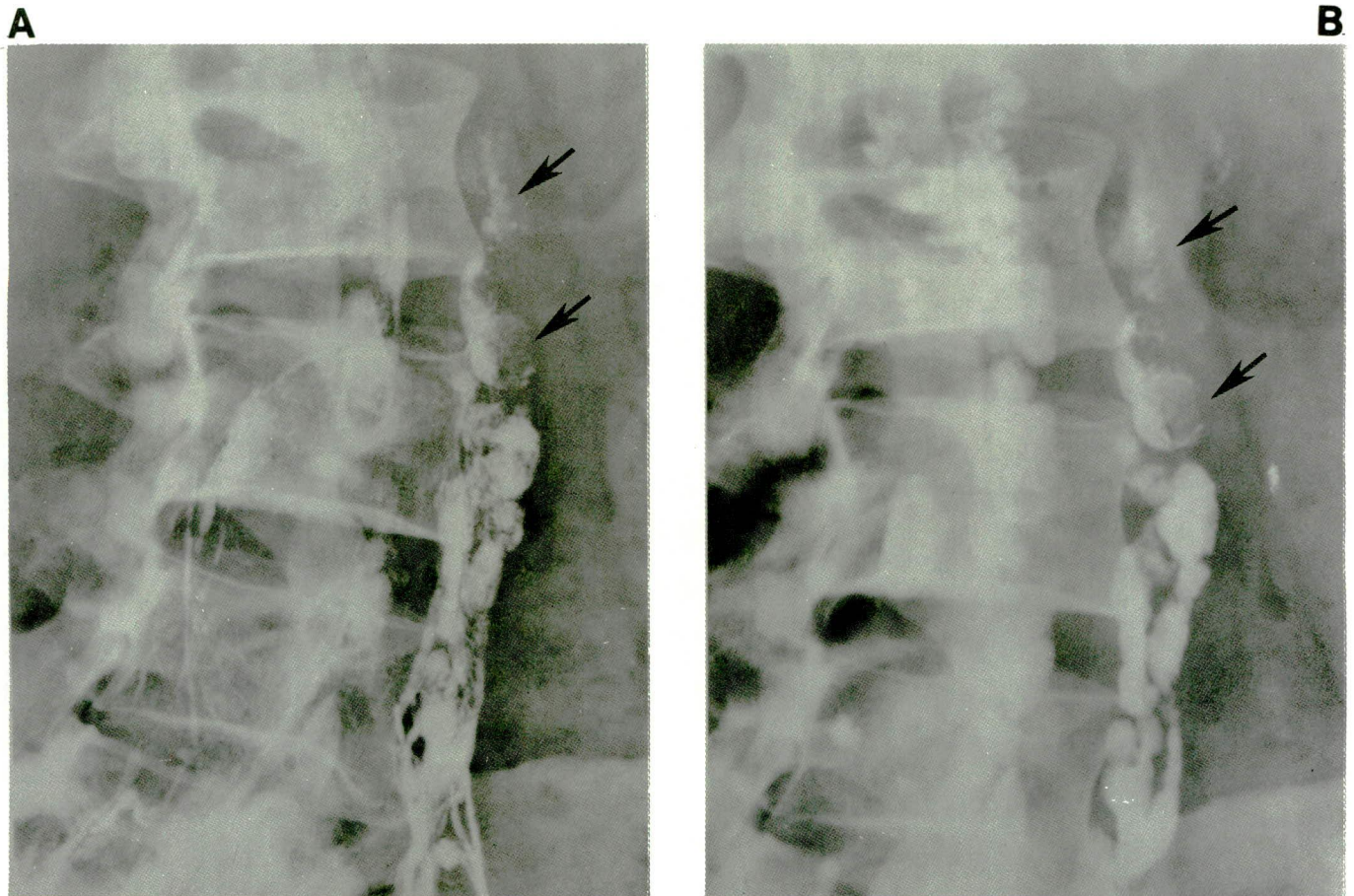


Figure 21 — Embryonal carcinoma of the right testicle with cross-over metastasis to the left paraaortic nodes (arrows)
A. Lymphatic phase.
B. Nodal phase.

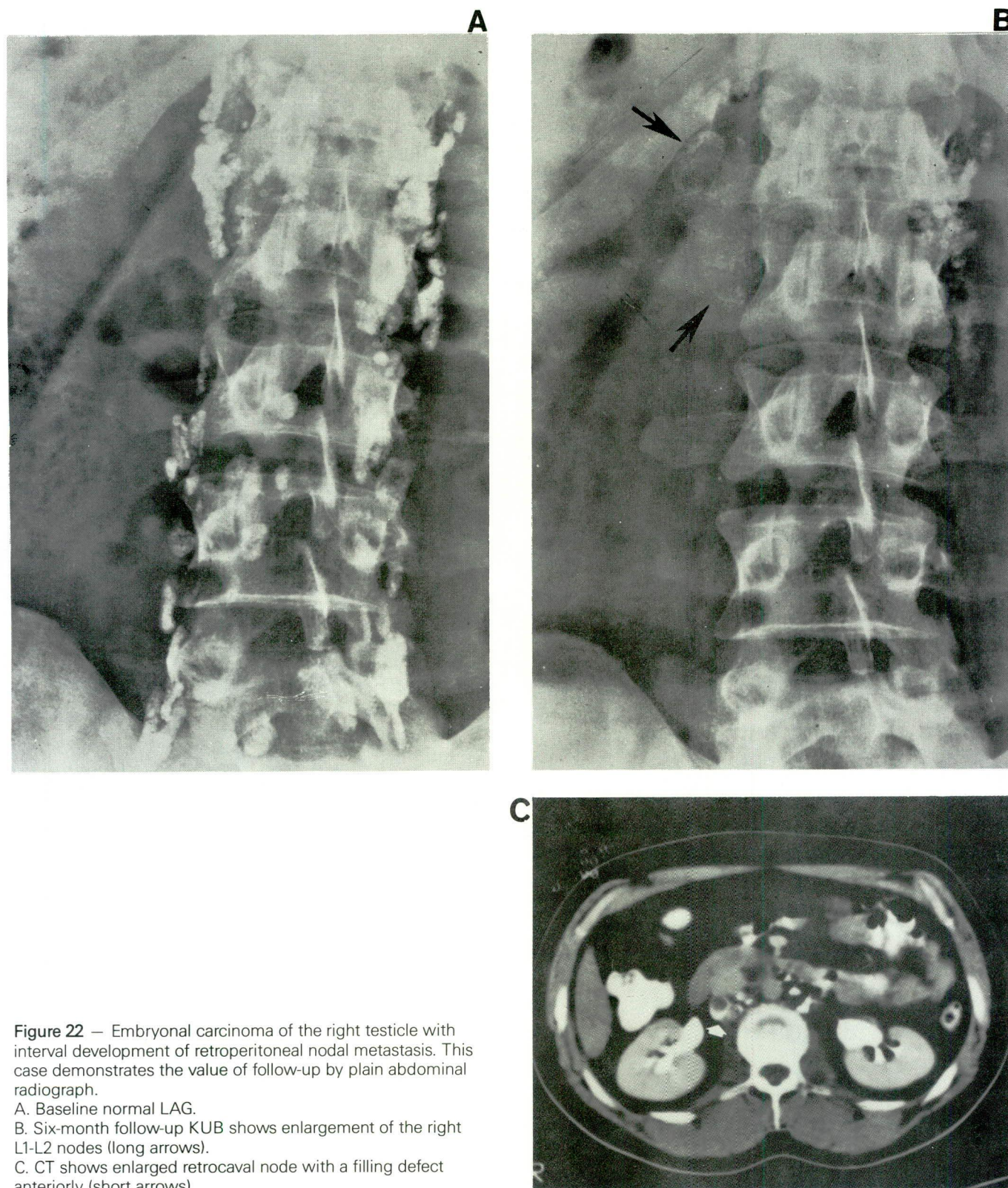


Figure 22 — Embryonal carcinoma of the right testicle with interval development of retroperitoneal nodal metastasis. This case demonstrates the value of follow-up by plain abdominal radiograph.

A. Baseline normal LAG.

B. Six-month follow-up KUB shows enlargement of the right L1-L2 nodes (long arrows).

C. CT shows enlarged retrocaval node with a filling defect anteriorly (short arrows).

Table 4 — Findings of LAG and CT in 103 patients with testicular tumors

	Lymphangiography	Computed tomography
Positive	53	50
Negative	50	53
Total	103	103

Table 5 — Pathological correlation in 39 patients with testicular neoplasms

	Lymphangiography	Computed tomography
Positive	29	26
False negative	2	5
Negative	7	7
False positive	1	1
Total	39	39
Sensitivity	29/31 = 93.5%	26/31 = 83.8%
Specificity	7/8 = 87.5%	7/8 = 87.5%
Accuracy	36/39 = 92.3%	33/39 = 84.6%

ly visualized by LAG, and CT better delineates the extent of the lesion. Given the lack of absolute superiority of either CT or LAG in the assessment of the nodal metastasis from nonseminomatous testicular tumors, Castellino and Margulin (1982) and Lien et al. (1983) recommended computed tomography as the initial imaging procedure because of its greater patient acceptability and broader scope. It was their recommendation that abnormal results may be confirmed histologically. If the cytological results were negative or if the result of the CT examination itself was negative, lymphangiography was recommended. However, at M.D. Anderson Hospital and Tumor Institute, LAG and CT are performed as complementary procedures in the initial evaluation. In the further management of these patients conventional radiographs of the abdomen are obtained at two-month intervals while CT is used at 6-12-month intervals (Table 6).

In seminomas, when LAG and CT are positive, radiotherapy is given to the ipsilateral iliac and bilateral retroperitoneal nodes up to the diaphragm. The mediastinum and both supraclavicular areas are also treated. In the presence of a negative lymphangiogram and CT, radiotherapy is given only to the level of the diaphragm.

In nonseminomatous malignancies in the past, a patient with a positive lymphangiogram and/or CT

Table 6 — Suggested Schedule of Tests for Patients with Testicular Carcinoma

Tests	Months						
	0	2	4	6	8	10	12
AFP	X	X	X	X	X	X	X
HCG	X	X	X	X	X	X	X
Chest radiograph	X	X	X	X	X	X	X
Lymphangiogram	X						
Computed tomography	X			X			
KUB		X	X	X	X	X	X

was treated by radiotherapy to the tumor dose of 2500 rads to the nodes up to the diaphragm. A retroperitoneal node dissection was then undertaken to remove residual tumor tissue with additional radiotherapy, 2500 rads, following the retroperitoneal node dissection. In the presence of negative lymphangiographic and CT findings, the retroperitoneal node dissection was undertaken initially. If the node dissection was negative, no further treatment was instituted.

At present with the stage I disease, normal markers, normal CT, and normal LAG, the patient is observed closely with no further treatment. Markers and follow-up examinations of the abdomen are done every two months. CT is performed every six months (Table 6). When there is a change in these parameters, chemotherapy is instituted.

In the presence of more widespread disease, stage II or stage III where chemotherapy is the initial therapeutic approach, LAG or CT is of assistance in determining the status of the retroperitoneal lymph nodes. After a favorable response to chemotherapy (that is, resolution of the pulmonary and retroperitoneal metastases), the patient is managed by utilizing the markers, CT and LAG. Surgery is reserved for instances where there are persistent defects in the nodes or residual tumor. Of twenty-five patients subjected to surgery with persistent changes on CT and/or lymphangiogram only one had residual tumor. If there is inadequate residual contrast material, a repeat lymphangiogram can be performed. We have repeated the study on many patients with a maximum of five lymphangiograms in a patient over a seven-year period. Given these circumstances, CT is of value for follow-up examinations as an alternative to repeating the lymphangiogram. While ultrasound is less specific than lymphangiogram and less sensitive than CT scan in the diagnosis of nodal metastases, it is of significant importance to diagnose postoperative lymphoceles following retroperitoneal node dissection (Figure 26) and as a guide for aspiration and drainage.

D. Magnetic resonance imaging

To date no studies have evaluated testicular lesions by surface coil*. In the assessment of metastases of testicular tumors to retroperitoneal lymph nodes and other abdominal structures, MRI and CT were nearly equivalent in their ability to correctly stage retroperitoneal adenopathy³¹. In this study, CT surpassed MRI in detection of abnormalities other than retroperitoneal lymph nodes. However, with the advent of oral contrast medium, and technical advances, MRI may improve staging accuracy and serve as an effective substitute for CT in the evaluation of the retroperitoneum³¹.

SECTION III: IMAGING IN SPECIAL CIRCUMSTANCES

A. Imaging in undescended testicles

The incidence of undescended testicle in the premature infant is 30% and in the term infant, 4%. In the adult population, this incidence is approximately 0.28%^{6,32}. This anomaly represents a complete or incomplete failure of the intraabdominal testes to descend into the scrotal sac via the inguinal canal. The malposition of the testes may be found at any point from mid abdomen to the inguinal canal. The undescended testicles may be unilateral or bilateral, and when unilateral, they are somewhat more common on the right side. Seventy percent of the undescended testicles are found in the inguinal canal⁶. Apart from being prone to trauma and resulting in sterility, there is now agreement that the risk of testicular cancer is 12 to 40 times greater in the undescended testes than those that have descended^{11,13}. Unfortunately, the placement of the undescended testicle within the scrotum does not preclude the possibility of a cancer developing at a later date (Fig. 8). Seminoma is the most common tumor arising from the undescended testicle¹¹. In a series of 23 patients reported from our institution, there were 14 cases of seminoma, six cases of embryonal carcinoma, two cases of mixed germ cell tumors and one case of teratoma³⁴. In the inguinal region, sonography can successfully detect the undescended testicle and the accuracy of

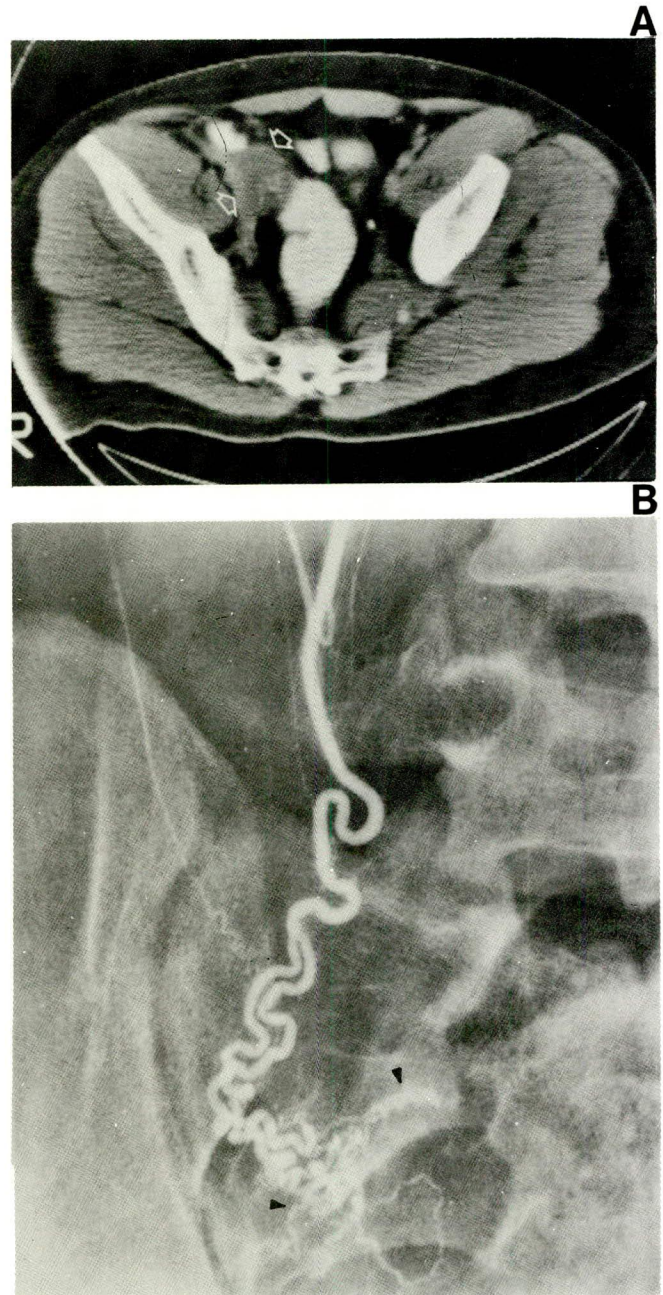


Figure 23 — Seminoma arising in an undescended testicle: 26-year-old male with leg edema due to a large right sided abdominal pelvic mass obstructing the inferior vena cava. The right testicle was absent from the scrotum. Biopsy of the mass revealed seminoma and the patient was treated with chemotherapy.

A. CT scan following 3 courses of chemotherapy shows dramatic shrinkage of the mass as compared to an outside study (not shown) and a residual mass medial to psoas muscle (arrows).

B. Testicular arteriography was performed to differentiate metastatic nodes from the presumed undescended testicle. This established that the mass on CT scan was indeed the testicle. Notice the vascular plexus outlining the testicle (arrowheads).

The surgically removed mass showed a fibrotic testicle with focal calcification and no residual tumor.

* Since the submission of this chapter, the following articles have appeared in the literature:

- 1) Baker LL, Hajek PC, Mattrey RF et al. — High-resolution MR imaging of the scrotum: a correlative anatomic-pathologic study. *Radiology*, 1986; 161 (P): 280.
- 2) Baker LL, Hajek PC, Burkhard TK, Dicapua L, Leopold GR, Hesselink JR, Mattrey RF — MR Imaging of the Scrotum: Normal anatomy. *Radiology*, 1987; 163: 89-92.
- 3) Baker LL, Hajek PC, Burkhard TK, Dicapua L, Landa HM, Leopold GR, Hesselink JR, Mattrey RF — MR imaging of the scrotum: pathologic conditions. *Radiology*, 1987; 163: 93-98.
- 4) Rholl KS, Lee JKT, Ling D, Heiken JP, Glazer HS — MR imaging of the scrotum with a high resolution surface coil. *Radiology*, 1987; 163: 99-103.

sonography and CT in this region is about the same⁶. However, in the abdominal and pelvic locations, CT scan is more sensitive^{6,33}. The sensitivity will increase when there is a complicating tumor arising from the testicle (Figure 23). In rare instances where computed tomography fails to detect the undescended testicle or differentiate metastatic nodes from the undescended testicle, spermatic venography or gonadal arteriography should be performed (Figure 23). Iliac node metastasis is rare in testicular tumors but may be seen *in tumors of undescended testicles*, alone or in combination with lumbar node metastasis. Prognosis of tumors arising from the undescended testicle is the same as in normally descended testicles³⁴.

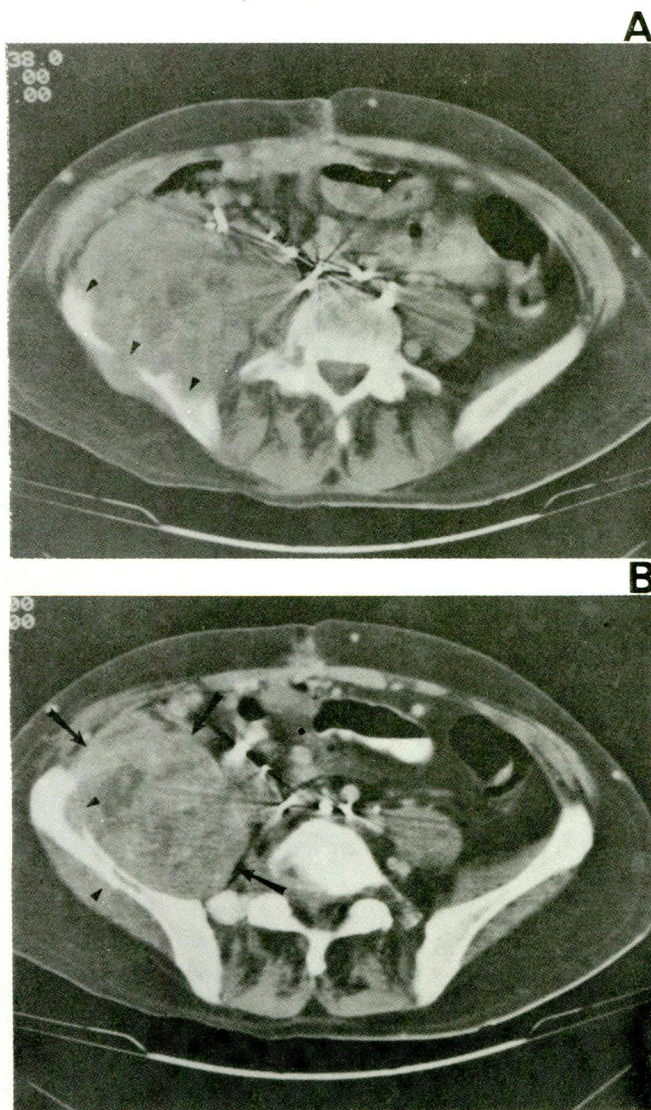


Figure 24 — Embryonal carcinoma of the testicle with extranodal metastasis to the muscle and bone. History of previous pelvic node dissection. CT scans at the level of the iliac crest (A) and iliac wing (B) show a large mass involving the ilio-psoas muscle (arrows) and destroying the iliac bone (arrowheads).

B. Extranodal metastasis in testicular tumors

Spread of the testicular tumors is usually in a predictable fashion via the lymphatic channels to the renal parahilar nodes, paraaortic nodes followed by supradiaphragmatic nodes in the posterior mediastinum and finally to the supraclavicular nodes^{3,7,8}. Hematogenous metastasis to the extranodal sites is common in certain testicular tumors such as choriocarcinoma and embryonal carcinoma particularly in instances where there is invasion of the tunica or epididymis^{5,11}.

The most common sites of extranodal metastases are the lungs (Figure 9) and liver (Figure 27), although metastases to brain (Figure 8) and bone also occur³. Metastasis to the lungs may occur in any type of germ cell tumors but is most common in choriocarcinomas^{3,11}. Husband and Bellamy have noticed unusual sites of extranodal metastasis in virtually every organ system such as the kidneys, adrenals, spleen, and muscle (Figure 24)³. Computed tomography plays a major role in detection of these metastases.

SECTION IV: INTERVENTIONAL TECHNIQUES IN THE DIAGNOSIS AND TREATMENT OF TESTICULAR TUMORS

A. Biopsy of the retroperitoneal nodes

Biopsy of the retroperitoneal nodes may be necessary to verify or exclude equivocal metastatic disease, determine the radiation therapy field and monitor the response of disease to treatment^{34,35,36}.

Occasionally, the nodes are replaced by tumor and the abnormality may not be apparent on LAG. On the other hand, non-neoplastic filling defects in the nodes such as caseous necrosis, fatty replacement and conglomerate lymph nodes may cause false positive results on LAG. Therefore, biopsy of the abnormal nodes may become an essential part of clinical management and staging^{35,36}.

Percutaneous biopsy may be done on an outpatient basis and will obviate the need for open biopsy. Since the node is left intact, therefore, response to treatment may be monitored by repeat biopsy³⁴. Percutaneous biopsy is also performed to establish the presence of metastases in the lung, liver, bone, soft tissues and brain³⁵.

Biopsy of the nodes may be performed transperitoneally or retroperitoneally using different modalities. If the nodes contain lymphangiographic contrast material, fluoroscopy (preferably biplane) is the best choice. CT is used when there is no contrast present within the nodes (Figure 25) or when the nodes are replaced by tumor and not opacified. In the instances where the nodal mass is large and accessible, ultrasound may be utilized as a guide. Results of percutane-

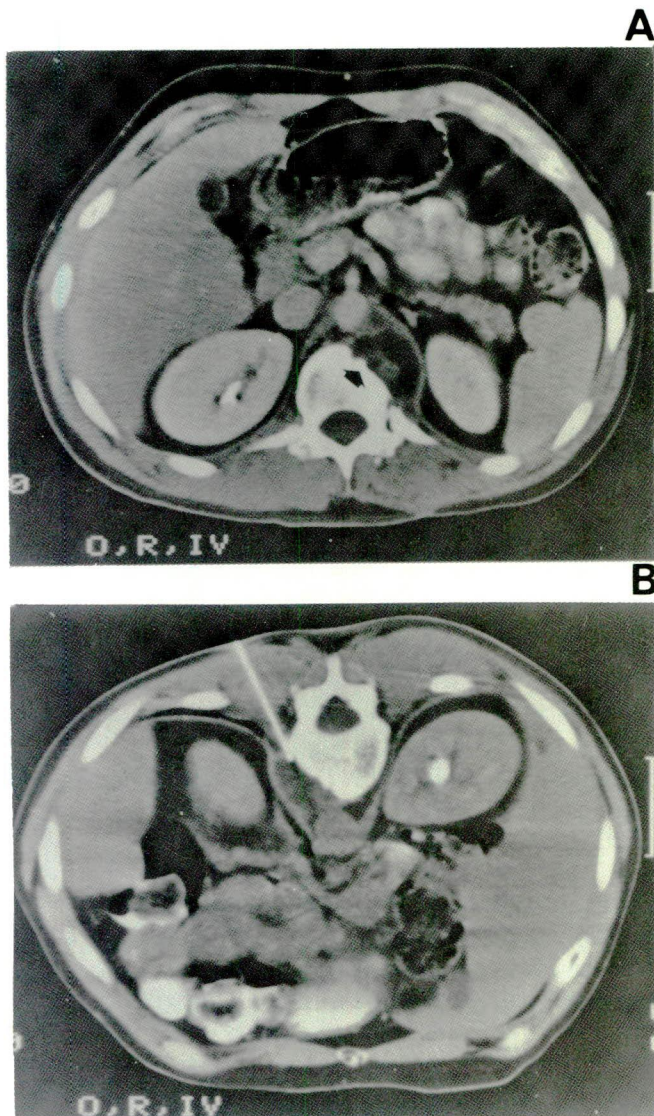


Figure 25 — CT guided biopsy of the lymph nodes. 31-year-old male with mixed germ cell tumor of the testicle (Embryonal carcinoma, EST and mature-immature teratoma), status postchemotherapy. A. CT scan shows low density left retrocrural mass resulting in bone destruction (arrow). B. CT scan with the patient in the prone position shows the biopsy needle in place. Biopsy revealed mature teratoma.

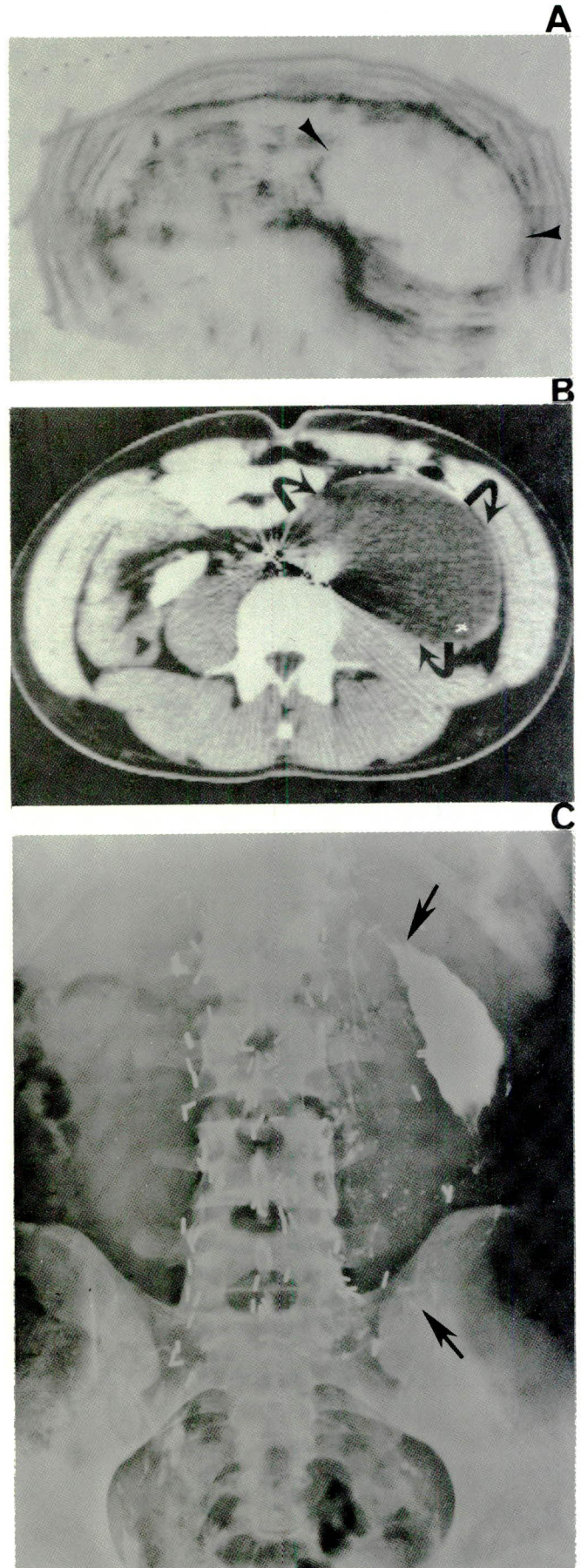


Figure 26 — Postoperative lymphocele. 20-year-old male with history of the right testicular mixed germ cell tumor and retroperitoneal lymph node dissection three months previously. A. Transverse sonogram showing large fluid collection in the left side of abdomen (arrowheads). One thousand ml of clear yellowish fluid containing lymphocytes aspirated. B. CT scan 3 days later showed reaccumulation of the fluid (curved arrows). Urogram (not shown) revealed displacement and obstruction of the left ureter. C. Abdominal film following drainage of 1200ml of fluid and injection of pantopaque and ethanol. Notice the contrast material outlining the large cavity (arrows).

ous lymph node biopsy has been reported to be accurate in 70-85% of metastatic carcinoma^{35,36}.

Transabdominal biopsy involves passage of a needle through various solid and hollow organs. Taking necessary precautions should obviate serious complications. The only relative contraindications to the procedure are bowel dilatation and abnormal coagulation profile.

B. Diagnosis and management of lymphoceles

Lymphoceles usually appear immediately after surgery but may be appreciated from days to months after retroperitoneal node dissection for testicular tumors. These may initially be asymptomatic and only manifest by an abdominal mass. However, they may become infected or cause venous, ureteral (Figure 26) or bowel obstruction^{7,37}.

Uncomplicated lymphocele would present as single or multiple fluid-containing masses with good sound transmission (Figure 26). Occasionally, they may contain debris. When abdominal sonogram is compromised by gas, CT scan can be used. CT will display a low-attenuation fluid collection in the case of uncomplicated lymphocele (Figure 26) and high attenuation in the complicated ones. Low CT numbers effectively exclude abscess or hematoma³⁷.

Lymphocele can also be diagnosed by lymphangiography, demonstrating a contrast/fluid level in the upright position. Management of the lymphocele should be either multiple needle aspirations or catheter drainage. The indications for catheter drainage are secondary infection, persistence or growth of larger collections, symptomatic patient, or signs of obstruction in the ureters or veins. The catheter drainage requires longer intervals, lasting an average of 18 days which is considerably longer than those for an abscess drainage. When the drainage ceases, a sclerosing agent is injected and the catheter is removed (Figure 26)³⁷.

C. Intraarterial chemotherapy, embolization and chemoembolization

Transcatheter procedures are occasionally used in metastatic disease from testicular neoplasms to the liver, and large retroperitoneal and pelvic nodes dependent upon the availability, the ability to isolate and selectively catheterize and treat through the arterial supply^{38,39}. These metastatic lesions are initially treated by intraarterial infusion of the chemotherapeutic agents (Figure 27). When the latter fails and radiotherapy becomes ineffective then devascularization of the lesions is attempted by embolization techniques with Ivalon, gelfoam or stainless steel coils. Chemoembolization, the combination of Ivalon or gelfoam with cisplatin, Actinomycin D, Mitomycin C, or Adriamycin has been effective in the management of liver,

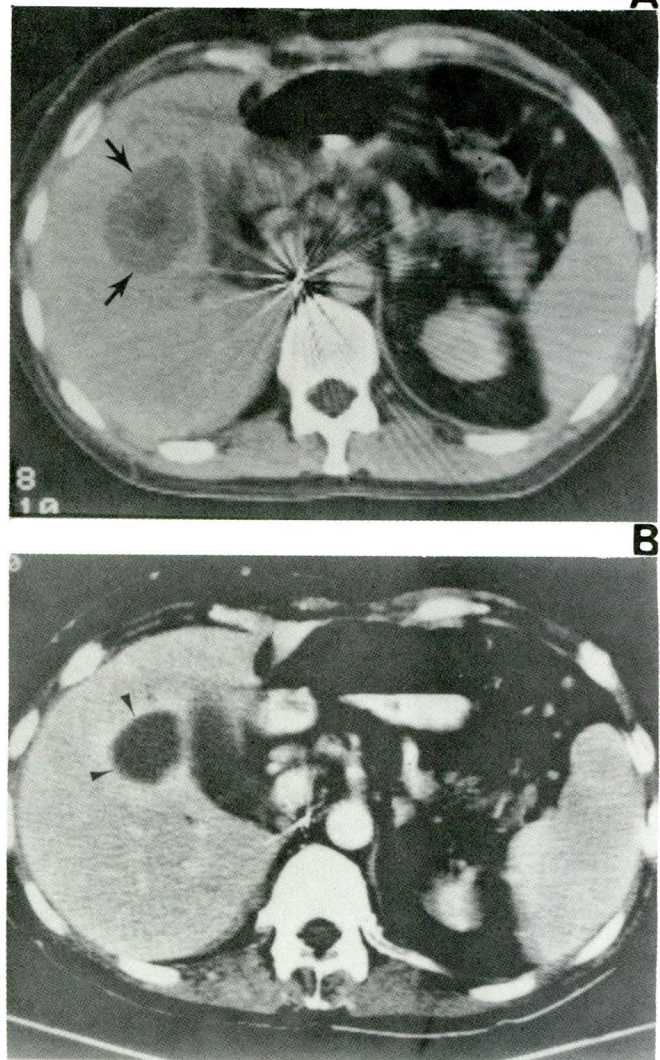


Figure 27 — Extranodal metastasis to the liver from embryonal carcinoma of the testicle treated with intraarterial chemotherapy.

A. CT scan shows a single lesion in the right lobe of the liver, the center of which has much lower attenuation (arrows).

B. CT scan following course of intraarterial 5-Fluorouracil and Mitomycin-C shows a decrease in the size of the hepatic lesion which now has a uniformly cystic density consistent with necrosis (arrowheads).

retroperitoneal nodes or osseous metastases. Treatment may provide a more demarcated and smaller avascular field for safe removal of the hepatic metastasis.

Embolization may also be utilized in patients with myelosuppression due to systemic or intraarterial infusion or in those patients who will be unable to tolerate further hepatic artery infusion chemotherapy. Failure of surgical resection is yet another indication for interventional therapy^{38,39}.

D. General interventional techniques

Additional interventional techniques including drainage procedures (abscess, urinary and biliary tract

obstruction, gastrostomy etc.), stent or balloon dilatation of stenoses of tubular structures, central venous catheter placement repositioning, foreign body retrieval, thrombolysis, etc. are available to assist in the management of the patient with a testicular neoplasm.

Acknowledgements

The authors wish to thank Margaret Meza for her secretarial help in the preparation of this manuscript and, Gene Swarc and Robert Czimny, from photography, for their technical assistance.

References

- Mostofi FK, Sobin LH — International histological classification of testicular tumors (no. 16): International Histological Classification of Tumors, Geneva, W.H.O. 1977.
- Pierce GB Jr, Abell MA — Embryonal carcinoma of the testis. *In* Sommers SC (ed.): Pathology Annual. New York, Appleton Century Crofts, 1970, p. 28.
- Husband JE, Bellamy EA — Unusual thoracoabdominal sites of metastases in testicular tumors. *AJR*, 1985; 145: 1165-1171.
- Lee JKT — Retroperitoneum, *In* Lee JKT, Sagel SS, Stanley RJ (Eds). Computed body tomography. New York, Raven Press, 1983; pp. 275-279.
- Krone KD, Carroll BA — Scrotal ultrasound. *Radiol Clinics of N Am*, 1985; 23(1): 121-139.
- Hricak H, Filly RA — Sonography of the scrotum. *Invest Radiol*, 1982; 18: 112-121.
- Jing BS, Wallace S — Lymphatic imaging of solid tumors: *In* Clouse ME and Wallace S (eds) Lymphatic imaging; Lymphography, computed tomography and scintigraphy. 2nd ed. Baltimore, Williams and Wilkins, 1985; pp. 348-368.
- Jing BS, Wallace S, Zornoza J — Metastases to retroperitoneal and pelvic nodes; Computed tomography and lymphangiography. *Radiol Clin of N Am*, 1982; 20(3): 511-530.
- Madrazo BL, Klugo RC, Parks JA, Diloroto R — Ultrasonographic demonstration of undescended testes. *Radiology*, 1979; 133: 181-183.
- Lee JKT, McClennan BL, Stanley RJ and Sagel SS — Utility of computed tomography in the localization of the undescended testis. *Radiology*, 1980; 135: 121-125.
- Robbins SL, Cotran RS, Kumar V — Male genital system. *In* Robbins SL, Cotran RS, Kumar V, eds. Pathologic Basis of Disease, 3rd ed. Philadelphia: WB Saunders, 1984; 1081-1108.
- Grantham JG, Charboneau JW, James EM et al. — Testicular neoplasms: 29 tumors studied by high-resolution US. *Radiology*, 1985; 157: 775-780.
- Subramanyam BR, Horii SC, Hilton S — Diffuse Testicular disease: sonographic features and significance. *AJR*, 1985; 145: 1221-1224.
- Shawker TH, Javadpour N, O'Leary T, Shapiro E, Krudy AG — Ultrasonographic detection of "burned-out" primary testicular germ cell tumors in clinically normal testes. *J Ultrasound Med*, 1983; 2: 477-479.
- Lupetin AR, King W, Rich P, Lederman RB — Ultrasound diagnosis of testicular leukemia. *Radiology*, 1983; 146: 171-172.
- Rayor RA, Scheible W, Brook WA, Leopold GR — High resolution ultrasonography in the diagnosis of testicular relapse in patients with acute lymphoblastic leukemia. *J Urol*, 1982; 128: 602-603.
- Glazer HS, Lee JKT, Melson GL, McClennan BL — Sonographic detection of occult testicular neoplasms. *AJR*, 1982; 138: 673-675.
- Rifkin MD, Kurtz AB, Pasto ME et al. — The sonographic diagnosis of focal and diffuse infiltrating intrascrotal lesions. *Urol Radiol*, 1984; 6: 20-26.
- Logothetis CJ, Samuels ML, Trindade A, Johnson DE — The growing teratoma syndrome. *Cancer*, 1982; 50: 1629-1635.
- Chong CD, Logothetis CJ, von Eschenbach AC, Ayala AG, Samuels ML — Successful treatment of pure endodermal sinus tumors in adult men. *J Clin Oncol* (in press).
- Lee JKT, McClennan BL, Stanley RJ, Sagel SS — Computed tomography in the staging of testicular neoplasms. *Radiology*, 1979; 130: 387-390.
- Zingas AP, Jain AB, Loredo RD, Kling GA — The spectrum of computed tomographic appearance of metastatic masses from testicular neoplasms. *CT*, 1984; 8: 53-60.
- Husband JE, Peckham MJ, MacDonald JS — The role of abdominal computed tomography in the management of testicular tumors. *Comput Tomogr*, 1980; 4: 1-16.
- Scatarige JC, Fishman EK, Kuhajda FP, Taylor GA, Siegelman SS — Low attenuation nodal metastases in testicular carcinoma. *J Comput Assist tomogr*, 1983; 7: 682-687.
- Soo CS, Bernardino ME, Chuang VP, Ordonez N — Pitfalls of CT findings in post-therapy testicular carcinoma. *J Comput Assist Tomogr*, 1981; 5: 39-41.
- Libshitz HI, Jing BS, Wallace S, Logothetis CJ — Sterilized metastases: A diagnostic and therapeutic dilemma. *AJR*, 1983; 140: 15-19.
- Stomper PC, Jochelson MC, Friedman EL, Garmick MB, Richie JP — CT evaluation of advanced seminoma treated with chemotherapy. *AJR*, 1986; 146: 745-748.
- Castellino RA, Marglin SE — Imaging of abdominal and pelvic lymph nodes: lymphography or computed tomography? *Invest Radiol*, 1982; 17: 433.
- Lien HH, Kolbenstvedt A, Talle K, Fossa SD, Klepp O, Ous S — Comparison of computed tomography, lymphography, and phlebography in 200 consecutive patients with regard to retroperitoneal metastases from testicular tumor. *Radiology*, 1983; 146: 129.
- Ellis JH, Bies JR, Kopecky KK, Klatte EC, Rowland RG, Donohue JP — Comparison of NMR and CT imaging in the evaluation of metastatic retroperitoneal lymphadenopathy from testicular carcinoma. *J Comput Assist Tomogr*, 1984; 8: 709-719.
- Bunce PL — Scrotal abnormalities. *In*: Glenn JF, ed. Urologic Surgery, New York: Harper & Row, 1975; 232-249.
- Lee JKT, McClennan BL, Stanley RJ, Sagel SS — Utility of CT in the localization of the undescended testis. *Radiology*, 1980; 135: 121-125.
- Jonsson K, Wallace S, Jing BS, Boyle LE, Johnson DE — Lymphangiography in patients with malignancy in a non-descended testicle. *The J of Urol*, 1978; 119: 614-617.
- Gothlin JH, Macintosh DK — Interventional radiology in the assessment of the retroperitoneal lymph nodes. *Radiol Clin of N Am*, 1979; 17: 461-473.
- Zornoza J — Needle biopsy of metastasis. *Radiol Clin of N Am*, 1982; 20: 569-590.
- Zornoza J, Hander P, Lukeman JM et al. — Percutaneous transperitoneal biopsy in urologic malignancies. *Urology*, 1977; 9: 395.
- Van Sonnenberg E, Wittich GR, Casola G et al. — Lymphoceles: Imaging characteristics and percutaneous management. *Radiology*, 1986; 161: 593-596.
- Soo CS, Chuang VP, Wallace S, Charnsangavej C — Interventional angiography in the treatment of metastases. *Radiol Clin of N Am*, 1982; 20: 591-600.
- Chuang VP, Soo CS, Wallace S — Ivalon embolization in abdominal neoplasms. *AJR*, 1981; 136: 729.