

Dental Profile of Patients Using Bisphosphonates at an Oncological Hospital

<https://doi.org/10.32635/2176-9745.RBC.2024v70n3.4731>

Perfil Odontológico dos Pacientes em Uso de Bisfosfonatos em um Hospital Oncológico

Perfil Dental de Pacientes que Utilizam Bisfosfonatos em um Hospital Oncológico

Jade Fontenele Tagliabue¹; Lísia Daltro Borges Alves²; Héilton Spíndola Antunes³

ABSTRACT

Introduction: Bisphosphonates are used in the treatment of bone conditions such as bone metastases from solid tumors and multiple myeloma. They can cause osteonecrosis of the jaw, an uncommon adverse effect that damages the patients' quality of life. **Objective:** Describe the clinical-epidemiological profile of patients using bisphosphonates at the National Cancer Institute. **Method:** Retrospective cross-sectional study based on patient's dentistry charts from 2018 to 2022. **Results:** Among the 108 patients included according to the study criteria, the majority were males (56.5%), over 50 years old (82.4%), diagnosed with multiple myeloma (76.9%). Disodium pamidronate was the most prescribed bisphosphonate (37.0%), at a dose of 90 mg (94.7%), administered monthly (74.3%), primarily for the treatment of multiple myeloma (77.8%). Dental consultations predominantly occurred before and during the use of bisphosphonate, although there was an increased frequency of consultations after use. Most of the patients had teeth and used unsatisfactory prosthetics. Tooth mobility was more common before bisphosphonate use (60.9%), with tooth extraction being the most demanded procedure at that time (45.8%). Subsequently and thereafter, dental scaling procedures were most frequently performed (51.3%). Periapical lesions were the most common radiographic findings before and during treatment, while bone rarefaction occurred afterward. Two patients (1.85%) developed jaw osteonecrosis. **Conclusion:** These results highlight a high demand for invasive dental care before treatment, loss of follow-up thereafter, and an increased need for conservative procedures to maintain oral health.

Key words: Mouth Neoplasms/drug therapy; Diphosphonates/adverse effects; Dental Care; Health Profile.

RESUMO

Introdução: Os bisfosfonatos são usados no tratamento de condições ósseas como metástases ósseas de tumores sólidos e mieloma múltiplo. Esses medicamentos podem causar osteonecrose dos maxilares, efeito adverso incomum que prejudica a qualidade de vida dos pacientes. **Objetivo:** Descrever o perfil clínico-epidemiológico dos pacientes em uso de bisfosfonatos do Instituto Nacional de Câncer. **Método:** Estudo transversal retrospectivo, com informações de prontuários de pacientes atendidos na seção de odontologia entre 2018 e 2022. **Resultados:** Entre os 108 pacientes incluídos de acordo com os critérios do estudo, a maioria era do sexo masculino (56,5%), acima de 50 anos (82,4%), com mieloma múltiplo (76,9%). O pamidronato dissódico foi o bisfosfonato mais prescrito (37,0%), na dose de 90 mg (94,7%), mensalmente (74,3%), para tratamento de mieloma múltiplo (77,8%). As consultas odontológicas ocorreram predominantemente antes e durante o uso dos bisfosfonatos, embora a quantidade de consultas tenha sido maior após o uso. Os pacientes foram majoritariamente dentados e usuários de próteses insatisfatórias. A mobilidade dentária foi mais comum antes do bisfosfonato (60,9%), e também nesse momento o procedimento que teve maior demanda foi a exodontia (45,8%). Já no decorrer e após, os mais realizados foram as raspagens (51,3%). As lesões periapicais foram os achados radiográficos mais comuns antes e durante o tratamento, e a rarefação óssea após. Dois pacientes (1,85%) apresentaram osteonecrose em mandíbula. **Conclusão:** Foram observados alta demanda de cuidados odontológicos invasivos antes do tratamento, perda de *follow-up* após e maior demanda por procedimentos conservadores para manutenção da saúde bucal.

Palavras-chave: Neoplasias Bucais/tratamento farmacológico; Difosfonatos/efeitos adversos; Assistência Odontológica; Perfil de Saúde.

RESUMEN

Introducción: Los bifosfonatos se utilizan en el tratamiento de condiciones óseas como las metástasis óseas de tumores sólidos y el mieloma múltiple. Pueden causar osteonecrosis de los maxilares, un efecto adverso poco común que afecta la calidad de vida de los pacientes. **Objetivo:** Describir el perfil clínico-epidemiológico de los pacientes que utilizan bifosfonatos en el Instituto Nacional del Cáncer. **Método:** Estudio transversal retrospectivo basado en registros de pacientes de la Sección de Odontología entre 2018 y 2022. **Resultados:** De los 108 pacientes incluidos según los criterios del estudio, la mayoría eran hombres (56,5%), mayores de 50 años (82,4%) y con mieloma múltiple (76,9%). El pamidronato disódico fue el bifosfonato más recetado (37,0%), en dosis de 90 mg (94,7%), administrado mensualmente (74,3%), principalmente para el tratamiento del mieloma múltiple (77,8%). Las consultas odontológicas ocurrieron predominantemente antes y durante el uso de bifosfonatos, aunque hubo un mayor número de consultas después del inicio del tratamiento. Los pacientes con dientes y los usuarios de prótesis inadecuadas eran la mayoría. La movilidad dental fue más común antes de iniciar el tratamiento con bifosfonatos (60,9%), siendo la extracción dental el procedimiento más demandado en ese momento (45,8%). Posteriormente y en adelante, los procedimientos más realizados fueron los raspados dentales (51,3%). Las lesiones periapicales fueron los hallazgos radiográficos más comunes antes y durante el tratamiento, mientras que la rarefacción ósea se observó posteriormente. Dos pacientes (1,85%) desarrollaron osteonecrosis de mandíbula. **Conclusión:** Estos resultados subrayan una alta demanda de atención dental invasiva antes del tratamiento, una pérdida de seguimiento posterior y una mayor necesidad de procedimientos conservadores para mantener la salud bucal.

Palabras clave: Neoplasias de la Boca/tratamiento farmacológico; Difosfonatos/efectos adversos; Atención Odontológica; Perfil de Salud.

¹⁻³Instituto Nacional de Câncer (INCA), Divisão de Pesquisa Clínica e Desenvolvimento Tecnológico. Rio de Janeiro (RJ), Brasil.

¹E-mail: jade.tagliabue12@edu.inca.gov.br. Orcid iD: <https://orcid.org/0000-0001-9686-1590>

²E-mail: lisia.alves@ensino.inca.gov.br. Orcid iD: <https://orcid.org/0000-0001-6779-8692>

³E-mail: hspindola@inca.gov.br. Orcid iD: <https://orcid.org/0000-0002-1076-8019>

Corresponding author: Jade Fontenele Tagliabue. Divisão de Pesquisa Clínica do INCA. Rua André Cavalcanti, 37 – Centro. Rio de Janeiro (RJ), Brasil. CEP 20230-130. E-mail: jade.tagliabue12@edu.inca.gov.br



INTRODUCTION

Bisphosphonates (BP) are a medication class whose pharmacological action is used to manage lesions from bone loss¹. They are highly relevant in treating bone metastasis of solid tumors, a common complication of cancer that affects the quality of life and survival of patients². In this context, they can also be used to treat multiple myeloma (MM) and other conditions, such as osteoporosis and osteopenia, in addition to metabolic changes like Page's disease and *osteogenesis imperfecta*³.

The mechanism of action of BP consists in specific inhibitory activity of osteoclasts, resulting in alteration of the body's bone remodeling process⁴. The most prominent and widely used BP is zoledronic acid, with more potent osteoclastic activity inhibitory properties than other drugs in the same class, such as sodium pamidronate.^{2,5}. Current treatment standards for bone metastasis involve BP and denosumab, a monoclonal antibody that inhibits RANK-L, structure responsible for osteoclastic formation and activation⁶⁻⁸. The advent of antiresorptive drugs is followed up by studies and case reports of medication-related osteonecrosis of the jaw (MRONJ)^{6,7}. Under this perspective, local risk factors in the oral cavity, such as the presence of infections and periodontal disease (PD), may be involved in the process of bone remodeling compromised by BP^{7,8}.

It is a common condition that is challenging to manage, with the potential to worsen patients' quality of life, which requires a multidisciplinary and integrated approach^{8,9}. Its incidence rate varies from 1% to 4% in the first two years to 3.8-18% after two years, for cancer patients using intravenous (IV) BP and denosumab, respectively¹⁰. It is worth highlighting that rates vary according to the drug type, therapeutic indication, route of administration, dosage and treatment duration¹¹.

The National Cancer Institute (INCA) is part of a highly specialized care network of the National Health System (SUS), being considered a reference center in oncological treatment in Brazil¹². Despite having incorporated BP to the institution's medication list¹³, there is a lack of studies by INCA related to adverse reactions to the medications. Thus, this study aims at describing the epidemiological-clinical profile of *Hospital do Câncer I* (HCI)/INCA patients using BP and followed up by the dentistry ward of the institution.

METHOD

Retrospective cross-sectional study conducted at HCI/INCA, with patients who received at least three consecutive doses of disodium pamidronate or zoledronic

acid IV between January 2018 and December 2022; who attended the dentistry ward and had a panoramic radiograph archived in the ward during the determined period. Patients who presented loss of follow-up of at least one year at their original practice or had the application of BP discontinued and a prior history of radiotherapy in the head and neck areas were excluded.

After applying the mentioned criteria, 108 cases comprised the final population of this study (Figure 1).

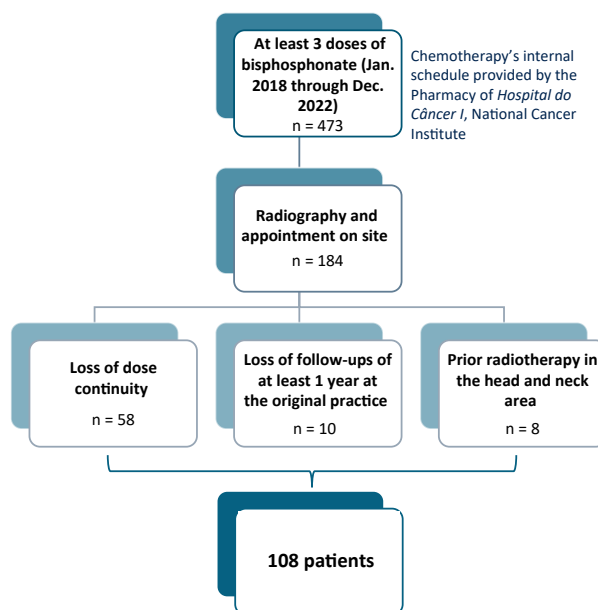


Figure 1. Flowchart of inclusion and exclusion criteria of patients in the study

The data were collected by a dental surgeon using a standard form. The physical and electronic records of the institution were analyzed, as well as the panoramic radiographs stored in the *Eagle 3D*® software. The interest variables included: sex, age, ethnic-race identification, oncological diagnosis and performed treatment, comorbidities at the time of diagnosis, as well as family history of cancer, smoking, alcoholism, and continuous use of medications. Medication indications, dosage of BP type, initial prescription and usage frequency were also recorded. Data concerning dental variables included time of dental appointment (before, during, or after use of BP), reasons for reporting to dentistry, and requester practice. At each ward visit, clinical information was collected regarding number of appointments held, oral features (number of teeth, prosthetics use and type, oral hygiene, gingivitis), tooth alterations (root remains, caries, dental fracture, tooth mobility), and soft tissue or bone changes. The performed procedures (tooth extraction, restoration, scraping), presence of osteonecrosis and delay in bone healing were also recorded.

For the radiograph assessment, the images were analyzed in an image viewer on a 17-inch monitor, in a low light environment by a trained dental surgeon at a single time. The analysis started on the first quadrant, then proceeded to the second, third and fourth quadrant. First, the number of teeth present were counted (considering all the elements on the radiograph – erupted, root remains, impacted tooth and supernumerary); then were analyzed the present elements (corono-apical direction); support structures, maxillary sinuses, condyles, coronoid processes and stylohyoid ligament¹⁴. The analysis observed the presence of impacted teeth, bone rarefaction, radiolucid images suggestive of periapical lesion, punched out aspect, dental alveolus in restoration, thickening of the periodontal ligament space and bone sequestration.

The data were registered in a standard data collection sheet and submitted to descriptive analysis through the Statistical Package for the Social Sciences (SPSS)¹⁵, version 17.0. Frequency tables were used for the qualitative variables, while descriptive measures such as median and minimum and maximum values were adopted for quantitative variables.

The total number of patients was considered for the analysis of epidemiological data, use of BP, and dental appointments. The total number of patients cared was considered at each moment for the data analysis of number of appointments, oral features, and procedures, given that each patient could have attended appointments in different moments. For the analysis of radiographic data, the total number of performed radiographs was accounted, considering that patients could have one or more radiographs.

This study has been approved by the Research Ethics Committee, report number 6166540 (CAAE (submission for ethical review): 66918223.1.0000.5274), in compliance with Resolution 466/2012¹⁶ of the National Health Council.

RESULTS

The studied population included 108 patients. Men were predominant (56.5%), with a median age of 60 years old (28-88 years), identified as brown (48.6%). Multiple myeloma (MM) was the most frequent oncological diagnosis (76.9%), and patients were treated mainly with chemotherapy (43.4%) and corticosteroid therapy (19.3%). At the time of diagnosis, most patients denied being smokers (62.0%), alcoholics (56.8%) or having a family history of cancer (56.6%). The main reported comorbidity was systemic hypertension (SH) (47.1%) followed by *diabetes mellitus* (DM) (15.7%), with 65.9% of these patients using continuous medication (Table 1).

Table 1. Epidemiological data

Variables	n	%
Sex		
Female	47	43.5
Male	61	56.5
Ethnicity/race^a		
White	41	39.0
Brown	51	48.6
Black	13	12.4
Age at diagnosis		
Median (min.-max.)	60.50 (28-88)	
28-37	4	3.7
38-47	15	13.9
48-57	24	22.2
58-67	45	41.7
68-77	18	16.7
78-87	1	0.9
88-97	1	0.9
Oncological diagnosis		
Multiple myeloma	83	76.9
Solitary plasmacytoma of the sacrum	2	1.9
Prostate	21	19.4
Lung	2	1.9
Oncological treatment^b		
Surgery	19	7.8
Corticosteroid therapy	47	19.3
Hormone therapy	20	8.2
Immunotherapy	2	0.8
Chemotherapy	106	43.4
Radiotherapy	46	18.9
Target therapy	4	1.6
Smoker^c		
Currently is	7	7.6
Used to be	28	30.4
Never was	57	62.0
Alcoholism^d		
Currently is	19	21.6
Used to be	19	21.6
Never was	50	56.8
Comorbidities at diagnosis^{e,f}		
Prior cancer	14	11.6
Heart disease	7	5.8
Diabetes mellitus	19	15.7
COPD	1	0.8

to be continued



Table 1. continuation

Variables	n	%
SH	57	47.1
Others	23	19.0
Family history of cancer at diagnosis^{a,h}		
No	43	56.6
Yes	33	43.4
Medications at diagnosis^{i,l}		
No	31	34.1
Yes	60	65.9

Captions: ^a = 3 absent data; ^b = patients could have undergone more than one oncological treatment; ^c = 16 absent data; ^d = 20 absent data; ^e = 2 absent data; ^f = patients may present more than one comorbidity; ^g = 32 absent data; ^h = patients may present more than one prior family history of cancer; ⁱ = 17 absent data; ^j = patients can use more than one medication; SH = systemic hypertension; and COPD = chronic obstructive pulmonary disease.

Isolated disodium pamidronate (37.0%) was the BP prescribed in most cases, with dosages of 90 mg (94.7%), in monthly applications (74.3%), for treating MM (77.8%). Patients took, in its majority, a total of five to nine doses, (37.0%), at a median of eight (8-2) doses.

The first appointment in the dentistry ward happened mostly before starting treatment (48.1%), with the objective of performing the pre-BP dental preparation (50.0%) and pre-hematopoietic stem cell transplantation (HPSCT) (25.5%), referred by the hematology ward (50.0%). Considering the continuity of dental appointments, most attended in only one moment: 24.2% attended during the use of BP and 22.2% attended before. Only 8.3% of patients attended the dental appointments in all moments.

As to the clinical characteristics, most individuals had teeth at the three moments of assessment (before, during, and after BP), with a respective median of 14.75, 13.96 and 15.33 teeth. Most patients presented satisfactory oral hygiene. The use of dental prosthetics predominated in every moment of assessment (80.0% before, 96.3% during, and 90.9% after BP), with unsatisfactory condition and total removable prosthetics (TRP) being the most predominant type. Tooth mobility was more observed before BP (60.9%), as well as the presence of root remains (19.6%). Caries lesions were more observed during BP use (44.6%) and few tooth fractures were observed in each assessment. Regarding alterations in the soft tissue, they were more frequent after BP use (23.3%), with findings such as traumatic ulceration due to maladapted prosthetics use and fistula in bone exposure area, recorded in the category of bone tissue change (6.7%) (Table 2).

Teeth extractions were predominant before BP use (45.8%), with a median of 2.38% (1-6) teeth extracted. Restorations and scraping were more observed during and after BP use (Table 3). During the use of BP, other procedures (20.0%) were recorded, such as low-power laser (LPL) for traumatic ulceration due to maladapted prosthetics, endodontic treatment in eight teeth, root burial, bone spicule removal, and fine needle aspiration biopsy (FNAB). It is worth mentioning that FNAB was conducted on a patient with prostate cancer that presented a radiolucid image in the jaw body, with the objective of investigating the diagnosis of bone metastasis. After BP (41.9%) endodontic treatment in five teeth and a root burial were observed. Additionally, adjustment and relining of a misfitting prosthesis, LPL, and photodynamic therapy for bone exposure were performed in one patient (Table 3).

Prior to BP, the radiographic findings were radiolucid images suggestive of periapical lesion, bone rarefaction and multiple radiolucid images in punched out aspect, that occurred in 32.8%, 22.4% and 15.5% of patients, respectively. This was observed during the use of BP in 25.0%, 25.0%, and 11.4% of patients, respectively. The presence of impacted tooth was verified in 6.9% of patients before BP and in 9.1% during the use of BP. After BP use, the most frequent finding was bone rarefaction (41.2%).

Regarding oral intercurrents related to BP, two patients presented healing delay after tooth extraction during BP, while three presented it after BP. Two patients were found to have bone exposure in the jaw after BP, presenting diffuse radiolucid image (osteolysis) associated to the radiopaque image (bone sequestration) compatible with the diagnosis of medication-related osteonecrosis of the jaw (MRONJ) (Figures 2A and B). The incidence of MRONJ in the studied population was 1.85%.

DISCUSSION

The present study verified the indication of bisphosphonates (BP) for patients diagnosed with multiple myeloma (MM) (76.9%), followed by prostate (19.4%) and lung cancer (1.9%), corroborating the usual indication of BP. The incidence of bone metastasis observed in the literature is of 65-90% for prostate cancer and 65-75% in breast cancer². As to MM, in 70-95% of cases patients had their bones compromised⁴. It is worth mentioning that INCA has an institutional division of four main units with different physical addresses. HCI is designed for oncological care of digestive, respiratory, urinary, head and neck, brain and vertebral spine, and skin cancers, as well as hematological neoplasms, while HCII cares for gynecological cancers and connective bone



Table 2. Recorded oral characteristics

Variables	Pre-BP (n=59)		During BP (n=78)		Post-BP (n=33)	
	n	%	n	%	n	%
Appointments on site						
Median (min.-max.)	3.19 (1-13)		3.21 (1-11)		5.03 (1-18)	
Had teeth						
No	7	11.9	10	12.8	5	15.2
Yes	52	88.1	63	80.8	24	72.7
Number of teeth present^b						
Median (min.-max.)	14.75 (0-32)		13.96 (0-32)		15.33 (0-32)	
Use of dental prosthetics						
No	5	20.0	1	3.7	1	9.1
Yes	20	80.0	26	96.3	10	90.9
State of dental prosthetics						
Unsatisfactory	6	60.0	11	78.6	4	57.1
Satisfactory	4	40.0	3	21.4	3	42.9
Oral hygiene^e						
Unsatisfactory	18	43.9	17	28.8	12	44.4
Satisfactory	23	56.1	42	71.2	15	55.6
Gingivitis^f						
No	38	86.4	52	92.9	21	77.8
Yes	6	13.6	4	7.1	6	22.2
Tooth mobility^g						
Absent	9	39.1	14	63.6	7	58.3
Present	14	60.9	8	36.4	5	41.7
Root remains^h						
Absent	41	80.4	53	91.4	23	92.0
Present	10	19.6	5	8.6	2	8.0
Lesions from cariesⁱ						
Absent	29	56.9	31	55.4	23	92.0
Present	22	43.1	25	44.6	2	8.0
Tooth fracture^j						
Absent	36	70.6	44	78.6	17	65.4
Present	15	29.4	12	21.4	9	34.6
Soft tissue changes^k						
Absent	43	87.8	54	88.5	23	76.7
Present	6	12.2	7	11.5	7	23.3
Bone changes^k						
Absent	48	98.0	60	98.4	28	93.3
Present	1	2.0	1	1.6	2	6.7

Captions: ^a = 5 and 4 absent data, respectively; ^b = 2, 24 and 9 absent data, respectively; ^c = 33, 49 and 21 absent data, respectively; ^d = 43, 61 and 24 absent data, respectively; ^e = 18, 19 and 6 absent data, respectively; ^f = 15, 22 and 6 absent data, respectively; ^g = 29, 46 and 15 absent data, respectively; ^h = 1, 10 and 3 absent data, respectively; ⁱ = 1, 12 and 3 absent data, respectively; ^j = 1, 12 and 2 absent data, respectively; ^k = 10, 17 and 3 absent data, respectively.



Table 3. Performed procedures

Variables	Pre-BP (n=59)		During BP (n=78)		Post-BP (n=33)	
	n	%	n	%	n	%
Exodontics ^a						
No	32	54.2	66	84.6	27	84.4
Yes	27	45.8	12	15.4	5	15.6
Number of teeth extracted						
Median (min.-max.)	2.38 (1-6)		2.83 (1-7)		2.6 (1-6)	
Restoration ^b						
No	40	67.8	50	65.8	20	62.5
Yes	19	32.2	26	34.2	12	37.5
Number of teeth restored						
Median (min.-max.)	2.50 (1-7)		2.42 (1-9)		4.38 (1-12)	
Scraping ^d						
No	39	66.1	37	48.7	20	62.5
Yes	20	33.9	39	51.3	12	37.5
Others ^c						
No	48	87.3	60	80.0	18	58.1
Yes	7	12.7	15	20.0	13	41.9

Captions: ^a = 1 absent data after BP; ^b = 2 and 1 absent data during and after BP, respectively; and ^c = 4, 3 and 1 absent data, respectively.

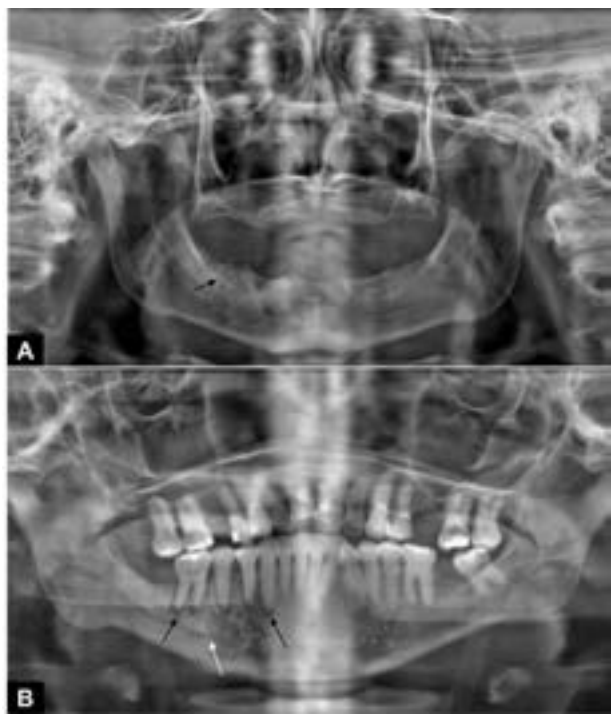


Figure 2. Panoramic radiograph of two patients with clinical and radiographic diagnosis of MRONJ; **A-** Change in the trabeculae, with increased medullary spaces in the posterior region of the right jaw (black arrow); **B-** Increase of space corresponding to the periodontal ligament of teeth 43 to 46 (white arrows), associated to the integrity of the bone crest of these elements and absence of probable odontogenic cause. There is also a change in the bone trabeculae, with an increase in the number of bone trabeculae, in the posterior region of the jaw on the right side, extending from the mesial of tooth 45 to the mesial root of tooth 46.

tissue tumors. Patients with breast tumors are treated in HCIII, and HCIV is designed for patients in palliative care¹³. Thus, the predominant number of MM reflects the population treated by the HCI, which was the field of study.

MM is a hematological neoplasm that is gradually increasing its incidence, with a discrete predominance in the male sex, appearing from the fifth decade of life¹⁷, corroborating the findings of this study in relation to patients' diagnosis. Regarding ethnic-race identification, most identified as brown, which is in line with the 2022 Demographic Census, in which most of the Brazilian population declared themselves as being brown¹⁸. Zoledronic acid is the most used BP due to its powerful therapeutic activity^{2,19}. However, the present study observed a greater use of disodium pamidronate, both isolated and in association with zoledronic acid. It's important to highlight that this is a third generation BP, incorporated to the SUS medication list since 2019. On the other hand, pamidronate has been removed from INCA in 2021, which would explain the divergence in comparison to the literature¹³.

Medication-related osteonecrosis of the jaw (MRONJ) is an adverse event related to the use of BP, especially for prolonged periods and intravenously (IV)^{20,21}. About 1.6% to 18% of oncological patients who use antiresorptive drugs develop MRONJ¹⁰ and, in around 90% of the cases,



there is a direct relationship to IV administration in high doses^{3,9}. From the sample, 1.85% presented MRONJ, corroborating the exposed, despite the reduced period of the study. However, the great loss of follow-up should be noted, since of the 108 patients, only 33 attended the post-BP assessment and 17 had a panoramic radiograph.

The dental treatment prior to the antiresorptive treatment has been associated to a reduction in the risk of developing MRONJ^{2,22} and the referral to a dental surgeon by the medical team is extremely important for the patient's therapeutic success²³. The present study observed that 48.1% of patients attended the first dental appointment before initiating treatment with BP. Similarly, at the Melbourne University Center in Australia, the referral rate was 45%, while in a multi-centric study in Seoul, South Korea, that rate was 30%^{24,25}. These data show that the referral rate is still low, reinforcing the need of awareness and continuous education of doctors that prescribe such therapies.

Considering that most patients had a MM diagnosis, and that in addition to BP use, pre-hematopoietic stem cell transplantation (HPSCT) might be included in its treatment²⁶, the main reasons for referral were pre-oncological treatment assessment, requested by the hematology team.

The number of dental appointments was greater during the BP treatment, with few follow-up records after the end of therapy. This corroborates some studies that suggest low adhesion to follow-up continuity in the long-term after finishing the oncological treatment. However, such a fact is still under documented in the literature about reasons for low adhesion to treatment^{27,28}.

A greater number of patients treated before and during BP treatment was observed, as well as a gradual increase in demand for appointments and procedures when analyzing the scenarios before, during, and after BP. It should be noted that the current literature lacks data on the dental appointments of this population, which impairs data comparison and assessment of reduction of adverse events such as MRONJ in patients who consulted a dental surgeon before treating with BP.

Before BP treatment, most individuals had teeth, however, a high frequency of tooth mobility, caries lesions, and root remains were observed, resulting in the need for procedures like tooth extraction and restorations. These data reflect a scenario where the Brazilian population is still not seeking regular and preventive dental care. In face of the oncological diagnosis and the indication of BP, there are high and multiple demands for interventionist procedures.

Oral prosthetics are a potential risk factor for developing MRONJ, with the posterior region on the lingual surface of the jaw being the most commonly

affected²⁹. In the present study, most patients reported the use of removable prosthetics that showed unsatisfactory conditions, which reinforce the need for follow-up and frequent adjustments in these patients.

Caries and periodontal disease (PD) can also become a risk factor for MRONJ, and an increasing number of studies suggest that, before surgical procedure, osteonecrosis may already be present through the dissemination of bacteria via dental structure and periodontal pockets up to the alveolar bone^{9,30}. Song et al. analyzed oncological patients with MRONJ and reported that tooth extraction is a causal factor in approximately two thirds of patients, while an oral extraction coincident with infection is found in about half the patients^{2,31}. Kwoen, et al.³² discuss that PD is the most common cause (>60%) of tooth extraction in patients aged 45 years and over, it can be an undervalued key factor for the occurrence of MRONJ³².

Caries lesions were more frequent during and after the use of BP when compared to the period before BP, which consequently caused a greater demand for restorations in these periods. In a similar way, a greater need for scraping was observed during and after treating with BP in comparison to the period before BP. These data probably represent the evolution of these diseases and show a concerning scenario in relation to active oral care and maintenance by the patients themselves³³.

D'Agostino, et al.⁹ showed in their study that oral hygiene was related to the classification of more severe stages of MRONJ. In this sense, the literature suggests that a preventive, continuous dental treatment focused on oral care is the key element for decreasing the incidence of this condition.

The most frequent finding in panoramic radiographs was the radiolucid image suggestive of periapical lesion, which is relevant in this context for being the consequence of an oral infection and thus representing a risk factor for MRONJ³⁴. The present study also highlighted bone rarefaction and multiple radiolucid images in punched out aspect, typical of MM, characterized by focal osteolytic lesions that may or may not present areas of bone rarefaction²⁹. Moreover, MRONJ can appear with alterations in the bone trabeculae with an aspect of rarefaction or changes associated to dental elements with no apparent odontogenic cause⁴, corroborating the radiographic findings of the two patients diagnosed with MRONJ in the study.

The limitations of the present study include those inherent to the retrospective cross-sectional model and the fact that the study relied on only one dental surgeon for data collection. The great number of absent data reflects the incompleteness of medical records, which interferes in the clinical profile analysis of the studied group of patients



and in the elaboration of a precise discussion. Additionally, there is an interpretive limitation of the results, since the patients with breast cancer were not included in the study due to the service's institutional division, resulting in a greater indication of BP for patients with MM¹⁸.

Regardless, the results showed high demands for dental care and the importance of dental preparation of patients submitted to treatment with BP, with the objective of preventing complications such as MRONJ. In addition, they reinforce the importance of inserting the dental surgeon as a fundamental part of the multidisciplinary team in oncology³⁵. It becomes relevant to understand the epidemiological profile and dental demands of patients cared by INCA, since this can guide the institution's service planning and the elaboration of public policies. These data, still scarce in the literature and coming from a high-complexity center, are valuable for improving the care offered to oncological patients and enriching the scientific literature, benefiting the scientific community and general population.

CONCLUSION

The present study showed a scenario of sodium pamidronate bisphosphonates (BP) prescribed to male patients diagnosed with multiple myeloma. The study observed a high demand for invasive dental care before treatment with BP, the loss of follow-up, and an increased need for conservative procedures to maintain oral health after starting the medication.

CONTRIBUTIONS

All the authors have substantially contributed to the study design, acquisition, analysis and interpretation of the data, wording, and critical review. They approved the final version for publication.

DECLARATION OF CONFLICT OF INTERESTS

There is no conflict of interest to declare.

FUNDING SOURCES

None.

REFERENCES

- Chien HI, Chen LW, Liu WC, et al. Bisphosphonate-related osteonecrosis of the jaw. *Ann Plast Surg.* 2021;86(2S Supl 1):S78-83.
- Wang L, Fang D, Xu J, et al. Various pathways of zoledronic acid against osteoclasts and bone cancer metastasis: a brief review. *BMC Cancer.* 2020;20(1059):1-10. doi: <https://doi.org/10.1186/s12885-020-07568-9>
- Ruggiero SL, Dodson TB, Aghaloo T, et al. American association of oral and maxillofacial surgeons' position paper on medication-related osteonecrosis of the jaws - 2022 update. *J Oral Maxillofac Surg.* 2022;80(5):920-43. doi: <https://doi.org/10.1016/j.joms.2022.02.008>
- Mhaskar R, Kumar A, Miladinovic B, et al. Bisphosphonates in multiple myeloma: an updated network meta-analysis. *Cochrane Database Syst Rev.* 2017;12(12):CD003188. doi: <https://doi.org/10.1002/14651858.cd003188.pub4>
- Corral-Gudino L, Tan AJH, del Pino-Montes J, et al. Bisphosphonates for paget's disease of bone in adults. *Cochrane Database Syst Rev.* 2017;12(12):CD004956. doi: <https://doi.org/10.1002/14651858.cd004956.pub3>
- Reid IR, Green JR, Lyles KW, et al. Zoledronate. *Bone.* 2020;137:115390. doi: <https://doi.org/10.1016/j.bone.2020.115390>
- Nicolatou-Galitis O, Schiødt M, Mendes RA, et al. Medication-related osteonecrosis of the jaw: definition and best practice for prevention, diagnosis, and treatment. 2019;127(2):117-35. *Oral Surgery, Oral Medicine, Oral Pathology and Oral Radiology.* doi: <https://doi.org/10.1016/j.oooo.2018.09.008>
- Antunes HS, Caldas RJ, Granzotto FCN, et al. Medication-related osteonecrosis of the jaw. *Rev Bras Odontol.* 2018;75:e1103. doi: <http://dx.doi.org/10.18363/rbo.v75.2018.e1103>
- Yarom N, Shapiro CL, Peterson DE, et al. Medication-related osteonecrosis of the jaw: MASCC/ISOO/ASCO clinical practice guideline. *J Clin Oncol.* 2019;(25):2270-90. Disponível em: <https://doi.org/10.1200/jco.19.01186>
- Ng TL, Tu MM, Ibrahim MFK, et al. Long-term impact of bone-modifying agents for the treatment of bone metastases: a systematic review. *Supportive Care in Cancer.* 2021;29(2):925-43. doi: <https://doi.org/10.1007/s00520-020-05556-0>
- Khan AA, Morrison A, Kendler DL, et al. Case-based review of osteonecrosis of the jaw (ONJ) and application of the international recommendations for management from the international task force on ONJ. *J Clin Densitom.* 20(1):8-24. doi: <https://doi.org/10.1016/j.jocd.2016.09.005>
- Instituto Nacional de Câncer José Alencar Gomes da Silva. Estimativa 2023: incidência de câncer no Brasil [Internet]. Rio de Janeiro: Instituto Nacional de Câncer José Alencar Gomes da Silva; 2022. [acesso 2024 maio 25]. Disponível em: <https://inca.gov.br/sites/ufu.sti.inca.local/files/media/document/estimativa-2023.pdf>
- Ministério da Saúde (BR). Portaria No 85, de 20 de dezembro de 2018. Torna pública a decisão de incorporar o ácido zoledrônico para doença de Paget no âmbito do Sistema Único de Saúde - SUS. *Diário Oficial da União, Brasília, DF.* 2018 dez 21; Edição 245; Seção I:830.



14. Mallya SM, Lam EWN. White and Pharoah's Oral Radiology: Principles and interpretation. 8 ed. New Delhi: Elsevier; 2018.
15. SPSS®: Statistical Package for Social Science (SPSS) [Internet]. Versão 17.0. [Nova York]. International Business Machines Corporation. [acesso 2023 mar 9]. Disponível em: https://www.ibm.com/br-pt/spss?utm_content=SRCWW&cp1=Search&cp4=43700077515785492&p5=p&gclid=CjwKCAjwgZCoBhBnEiwAz35Rwiltb7s14pOSLocnooMOQh9qAL59IHVc9WP4ixhNTVMjenRp3-aEgxoCubsQAvD_BwE&gclsrc=aw.ds
16. Conselho Nacional de Saúde (BR). Resolução n° 466, de 12 de dezembro de 2012. Aprova as diretrizes e normas regulamentadoras de pesquisas envolvendo seres humanos. Diário Oficial da União, Brasília, DF. 2013 jun 13; Seção I:59.
17. Hemminki K, Försti A, Houlston R, et al. Epidemiology, genetics and treatment of multiple myeloma and precursor diseases. *Int J Cancer*. 2021;149(12):1980-96. doi: <https://doi.org/10.1002/ijc.33762>
18. Instituto Brasileiro de Geografia e Estatística. Censo demográfico 2022 [Internet]. Rio de Janeiro: IBGE; 2023. [acesso 2024 abr 24]. Disponível em: <https://www.ibge.gov.br/estatisticas/sociais/populacao/22827-censo-demografico-2022.html?=&t=downloads>
19. Hoefert S, Yuan A, Munz A, et al. Clinical course and therapeutic outcomes of operatively and non-operatively managed patients with denosumab-related osteonecrosis of the jaw (DRONJ). *J Craniomaxillofac Surg*. 2017;45(4):570-8. doi: <https://doi.org/10.1016/j.jcms.2017.01.013>
20. Kawahara M, Kuroshima S, Sawase T. Clinical considerations for medication-related osteonecrosis of the jaw: a comprehensive literature review. *Int J Implant Dent*. 2021;7(1):4. doi: <https://doi.org/10.1186/s40729-021-00323-0>
21. Jara MA, Varghese J, Hu MI. Adverse events associated with bone-directed therapies in patients with cancer. *Bone*. 2022;158:115901. doi: <https://doi.org/10.1016/j.bone.2021.115901>
22. Dunphy L, Salzano G, Gerber B, Graystone J. Medication-related osteonecrosis (MRONJ) of the mandible and maxilla. *BMJ Case Rep*. 2020;13(1). doi: <https://doi.org/10.1136/bcr-2018-224455>
23. Wan JT, Sheeley DM, Somerman MJ, et al. Mitigating osteonecrosis of the jaw (ONJ) through preventive dental care and understanding of risk factors. *Bone Res*. 2020;8:14. doi: <https://doi.org/10.1038/s41413-020-0088-1>
24. Raj DV, Abuzar M, Borromeo GL. Bisphosphonates, healthcare professionals and oral health. *Gerodontology*. 2016;33(1):135-43. doi: <https://doi.org/10.1111/ger.12141>
25. Kim JW, Jeong SR, Kim SJ, et al. Perceptions of medical doctors on bisphosphonate-related osteonecrosis of the jaw. *BMC Oral Health*. 2016;16(92):1-5.
26. Al Hamed R, Bazarbachi AH, Malard F, et al. Current status of autologous stem cell transplantation for multiple myeloma. *Blood Cancer*. 2019;9(4):44. doi: <https://doi.org/10.1038/s41408-019-0205-9>
27. Sales GS, Vasconcelos RMA, Fernandes LM, et al. Impactos da pandemia de COVID-19 sobre a adesão ao tratamento oncológico: uma revisão integrativa. *Rev Baiana Saúde Pública*. 2022;46(3):276-90; doi: <https://doi.org/10.22278/2318-2660.2022.v46.n3.a3759>
28. Telayneh AT, Tesfa M, Woyraw W, et al. Time to lost to follow-up and its predictors among adult patients receiving antiretroviral therapy retrospective follow-up study Amhara Northwest Ethiopia. *Sci Rep*. 2022;12(2916):1-11. doi: <https://www.nature.com/articles/s41598-022-07049-y>
29. Kurşun BÜ, Akan E. Evaluation of trabecular bone changes according to the type of prosthesis in patients using bisphosphonates: a retrospective study. *Braz Oral Res*. 2023;37:e089. doi: <https://doi.org/10.1590/1807-3107bor-2023.vol37.0089>
30. Kim HY. Review and update of the risk factors and prevention of antiresorptive-related osteonecrosis of the jaw. *Endocrinol Metab (Seoul)*. 2021;36(5):917-27. doi: <https://doi.org/10.3803/enm.2021.1170>
31. Song M. Dental care for patients taking antiresorptive drugs: a literature review. *Restor Dent Endod*. 2019;44(4):e42. doi: <https://doi.org/10.5395/rde.2019.44.e42>
32. Kwoen MJ, Park JH, Kim KS, et al. Association between periodontal disease, tooth extraction, and medication-related osteonecrosis of the jaw in women receiving bisphosphonates: a national cohort-based study. *J Periodontol*. 2023;94(1):98-107. doi: <https://doi.org/10.1002/jper.21-0611>
33. Peres MA, D Macpherson LM, Weyant RJ, et al. Oral diseases: a global public health challenge. *Lancet*. 394(10194):249-60. [https://doi.org/10.1016/s0140-6736\(19\)31146-8](https://doi.org/10.1016/s0140-6736(19)31146-8)
34. Rao NJ, Wang JY, Yu RQ, et al. Role of periapical diseases in medication-related osteonecrosis of the jaws. *Biomed Res Int*. 2017;2017:1560175.
35. Alves LDB, Antunes HS, Santos Menezes AC, et al. Strategies for the dentist management of cancer patients: narrative literature review. *J Cancer Prev Curr Res*. 2021;12(4):111-21. doi: <https://doi.org/10.1155/2017/1560175>

Recebido em 11/6/2024
Aprovado em 22/7/2024

Associate-editor: Daniel Cohen Goldemberg. Orcid iD: <https://orcid.org/0000-0002-0089-1910>
Scientific-editor: Anke Bergmann. Orcid iD: <https://orcid.org/0000-0002-1972-8777>



Este é um artigo publicado em acesso aberto (Open Access) sob a licença Creative Commons Attribution, que permite uso, distribuição e reprodução em qualquer meio, sem restrições, desde que o trabalho original seja corretamente citado.